

# Orofacial Disease: Update For The Dental Clinical Team: 3. White Lesions

Crispian Scully and Stephen Porter

**Abstract:** White lesions usually contain an increased amount of keratin. Some are rare congenital conditions, such as white sponge naevus and dyskeratosis congenita, unlikely to be seen in general dental practice. Inflammatory causes include candidosis and hairy leukoplakia, both now common in HIV disease. Non-infective causes include the common lesion of lichen planus, and the less common condition lupus erythematosus. Neoplastic and possibly preneoplastic causes include carcinoma, keratoses and leukoplakia. This article discusses the more common causes of oral white lesions. The first article in this series presented several general observations on diagnosis and treatment which should be borne in mind in relation to this article.

Dent Update 1999; 26: 123-129

**Clinical Relevance:** It is important to recognize white lesions since some are potentially malignant or herald systemic disease.

White lesions appear white usually because they are composed of thickened keratin, which assumes a white appearance when wet. Most were formerly known as 'leukoplakia'. However, there has been considerable misunderstanding and confusion about this term, and an attempt was made to address this by the World Health Organization (WHO Collaborating Reference Centre for Oral Precancerous Lesions, 1978) when they defined leukoplakia as:

*a white patch or plaque that cannot be characterized clinically or pathologically as any other disease.*

The term, therefore, specifically excluded

Crispian Scully, PhD, MD, MDS, FDS RCPS, FFD RCS, FDS RCS, FDS RCSE, FRCPath, FMedSci, Professor, and Stephen Porter, PhD, MD, FDS RCSE, FDS RCS, Professor, Eastman Dental Institute for Oral Health Care Sciences, University of London.

defined clinicopathologic entities such as lichen planus and candidosis but still incorporated white lesions caused by friction or other trauma, and offered no comment on the presence of dysplasia. An international seminar in 1983 agreed that leukoplakia should be defined as:

*a whitish patch or plaque that cannot be characterized clinically or pathologically as any other disease and which is not associated with any physical or chemical causative agent except the use of tobacco.*

Oral white lesions have a range of causes (these are summarized in Table 1).

### CONGENITAL LESIONS

#### Fordyce's Spots

In some people sebaceous glands may be seen as creamy-yellow dots along the

border between the vermillion and the oral mucosa (Figure 1). These are common. They are not usually evident in infants, but they appear in children after the age of 3 years, increase during puberty and then again in later adult life. No treatment is indicated.

#### White Sponge Naevus

##### Aetiology

This is a rare benign autosomal dominant condition.

##### Clinical Features

Asymptomatic, diffuse, bilateral white lesions with a shaggy or spongy, wrinkled surface are seen:

- typically on the buccal mucosa;
- sometimes on the tongue, floor of mouth, or elsewhere;
- occasionally in the pharynx, oesophagus, nose, genitals and anus.

##### Diagnosis and Management

White sponge naevus is usually diagnosed from the clinical features; biopsy is confirmatory but rarely indicated. No reliable treatment, other than reassurance

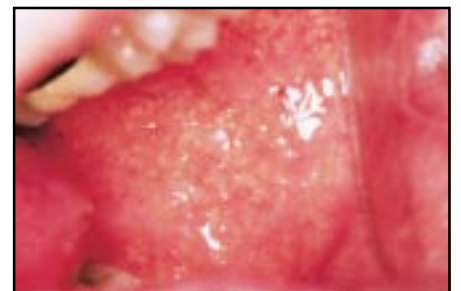

Figure 1. Fordyce's spots.

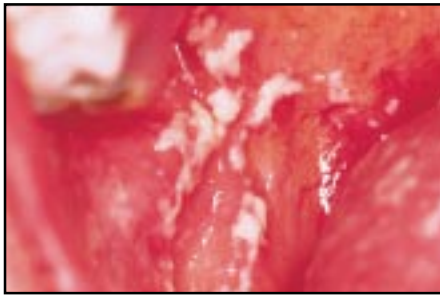


Figure 2. Oral thrush.

that the condition is benign, is available or needed.

### Dyskeratosis Congenita

This is another rare autosomal dominant condition, similar to white sponge naevus. However, the lesions may be premalignant and specialist referral is indicated.

## INFECTIVE LESIONS

### Candidosis (candidiasis)

*Candida albicans* is a harmless commensal in the mouths of nearly 50% of the population but, under suitable circumstances—such as when there is a disturbance in the oral flora or decrease in immune defences—it can become an opportunistic pathogen.

*Candida* often then produces white oral lesions, red, or mixed white and red lesions, and may cause soreness. Infection is increasingly being seen, mainly because of HIV infection and other

immunocompromising states, and now there is an increase both in infection by non-*albicans* species of *Candida* and resistance to antifungals.

### Thrush (Acute Pseudomembranous Candidosis)

The term ‘thrush’ is used for the white fleck appearance of acute candidosis which is considered to resemble the appearance of the breast of a thrush (Figure 2).

#### Aetiology

Thrush is rare in healthy patients. It may be seen in healthy neonates, however, or where the oral microflora is disturbed by antibiotics, corticosteroids or xerostomia. Oropharyngeal thrush occasionally complicates the use of corticosteroid inhalers (Table 2). Immune defects, especially HIV infection, immunosuppressive treatment, leukaemias and lymphomas, cancer and diabetes predispose to thrush.

#### Clinical Features

Thrush presents as white or creamy plaques that can be wiped off to leave a red base. Lesions occur mostly in the upper buccal vestibule posteriorly and the soft palate.

#### Diagnosis and Management

The diagnosis is usually clinical, but a Gram smear (for hyphae) or oral rinse may help. Differentiation from lichen planus is the main problem, although very

<b>Congenital:</b>
● Fordyce's spots
● White sponge naevus
● Dyskeratosis congenita
<b>Inflammatory</b>
<b>Infective:</b>
● Candidosis
● Hairy leukoplakia
● Papilloma and other HPV lesions
● Syphilitic leukoplakia
● Koplik's spots (measles)
<b>Non-infective:</b>
● Lichen planus
● Lupus erythematosus
<b>Neoplastic and possibly preneoplastic:</b>
● Leukoplakia
● Keratoses
● Carcinoma
● Submucous fibrosis
<b>Others:</b>
● Burns
● Drugs
● Grafts
● Scars

Table 1. Oral white lesions.

occasionally Koplik's or Fordyce's spots confuse the tyro. It is important to determine and treat any predisposing cause.

Antifungals such as nystatin oral suspension or pastilles, amphotericin lozenges, miconazole gel or tablets or fluconazole tablets are indicated. Chlorhexidine also has some antifungal activity.

### Chronic Mucocutaneous Candidosis

Chronic mucocutaneous candidosis is the term given to a number of rare congenital syndromes characterized by persistent candidosis affecting the mouth (Figure 3), skin, nails (Figure 4) and other areas. Specialist care is indicated.

### Candidal Leukoplakia (Chronic Hyperplastic Candidosis)

#### Aetiology

Smoking appears to predispose to this lesion (Table 3), although the exact aetiology is unclear. *Candida albicans* can induce epithelial proliferation and can produce nitrosamines which might be carcinogenic.

#### Clinical Features

Chronic oral candidosis produces a leukoplakia typically in the dorsum of the tongue and the post-commissural buccal mucosa (Figure 5). The plaque is

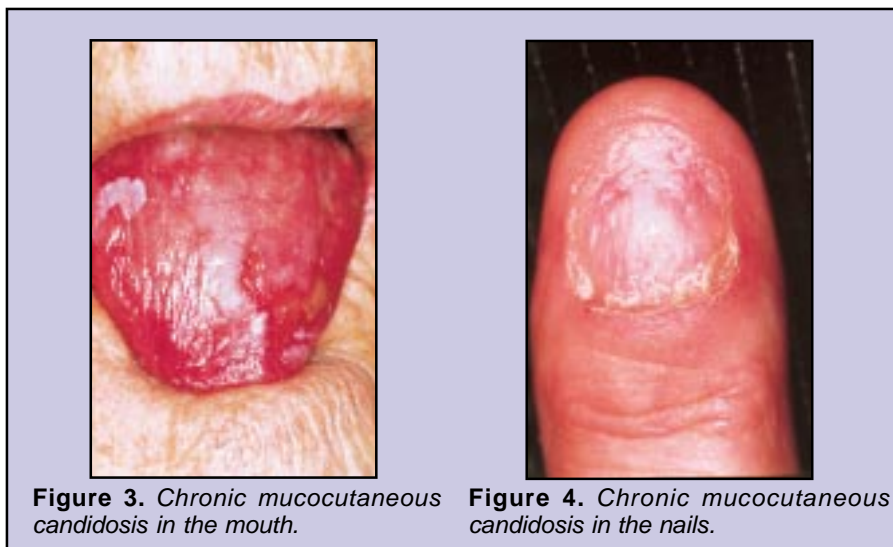


Figure 3. Chronic mucocutaneous candidosis in the mouth.

Figure 4. Chronic mucocutaneous candidosis in the nails.

<p><b>Aetiology:</b></p> <ul style="list-style-type: none"> <li>● Drugs: antibiotics, corticosteroids immunosuppressives</li> <li>● Xerostomia</li> <li>● Immune defects</li> </ul> <p><b>Clinical features:</b></p> <ul style="list-style-type: none"> <li>● White or creamy plaques that can be wiped off to leave a red base</li> </ul> <p><b>Incidence:</b></p> <ul style="list-style-type: none"> <li>● Rare in healthy patients</li> </ul> <p><b>Management:</b></p> <ul style="list-style-type: none"> <li>● Clinical diagnosis usually</li> <li>● Treat predisposing cause</li> <li>● Antifungals</li> </ul>
--

**Table 2. Thrush.**

variable in thickness and often rough or irregular in texture, or nodular with an erythematous background (speckled leukoplakia). It is distinguishable only by biopsy from other leukoplakia-like conditions. Candidal leukoplakia is potentially malignant.

**Diagnosis and Management**

Unlike acute candidosis (thrush), the plaque cannot be wiped off, but fragments can be detached by firm scraping. Gram-staining then shows candidal hyphae embedded in clumps of detached epithelial cells. However, biopsy is indicated in view of the possibility of dysplasia, and a specialist opinion is warranted.

The patient should stop smoking. Antifungal treatment is indicated but if the lesion does not resolve after four weeks of therapy it is better to remove it by scalpel or laser excision.

**Hairy Leukoplakia**

Hairy leukoplakia was described in detail in the preceding article of this series. The hairy leukoplakia seen in immunocompromised persons appears to have no premalignant predisposition.

<p><b>Aetiology:</b></p> <ul style="list-style-type: none"> <li>● Unclear: smoking predisposes</li> </ul> <p><b>Clinical features:</b></p> <ul style="list-style-type: none"> <li>● Typically at commissures</li> <li>● Often speckled</li> </ul> <p><b>Incidence:</b></p> <ul style="list-style-type: none"> <li>● Uncommon</li> </ul> <p><b>Management:</b></p> <ul style="list-style-type: none"> <li>● Biopsy</li> <li>● Antifungals</li> <li>● Stop smoking</li> <li>● Remove (scalpel, laser)</li> </ul>
--

**Table 3. Candidal leukoplakia.**

**Papilloma**

This is an uncommon lump with an anemone-like appearance, seen mainly in adults.

**Aetiology**

Human papillomaviruses (HPV).

**Clinical Features**

This benign neoplasm of epithelium appears most often at the junction of the hard and soft palate (Figure 6). The papilloma is a cauliflower-like lesion with a whitish colour, and may resemble a wart. Papillomas of normal colour may be confused with the more common fibroepithelial polyps (fibrous lumps), although the latter are most common at sites of potential trauma.

Unlike papillomas of the larynx or bowel, which may undergo malignant transformation, papillomas in the oral cavity appear to remain benign.

**Diagnosis and Management**

Oral papillomas should be excised and examined histologically to establish a correct diagnosis. Excision must be total, deep and wide enough to include any abnormal cells beyond the zone of the pedicle.

**Verrucae**

These warts are usually seen on the lips of children who have warts on their fingers but are uncommon.

**Aetiology**

These are also caused by HPV—usually transmitted from skin warts (verruca vulgaris). The prevalence is higher in patients with sexually transmitted diseases or who are immunocompromised.

**Clinical Features**

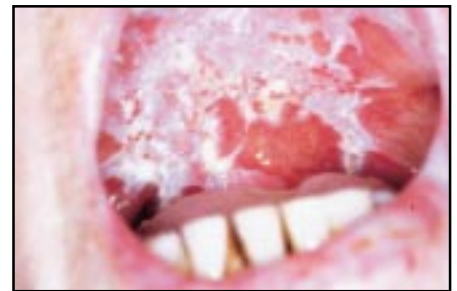Verrucae are predominantly as warty or smooth-surfaced papules.

**Management**

Verrucae are removed by excision biopsy, laser or cryosurgery, topical podophyllin or intralesional alpha interferon.

**Condyloma Acuminata**

Condylomata (genital warts) are usually seen on the tongue or fauces in sexually active persons.



**Figure 5. Candidal leukoplakia.**

**Aetiology**

Condylomata are caused by HPV, usually transmitted from ano-genital lesions. A higher prevalence is seen in patients with sexually transmitted diseases or who are immunocompromised.

**Clinical Features**

Condyloma acuminata are found mainly on the tongue or palate as warty or smooth-surfaced papules.

**Management**

As with verrucae, treatment is by excision biopsy, laser or cryosurgery, topical podophyllin or intralesional alpha interferon.

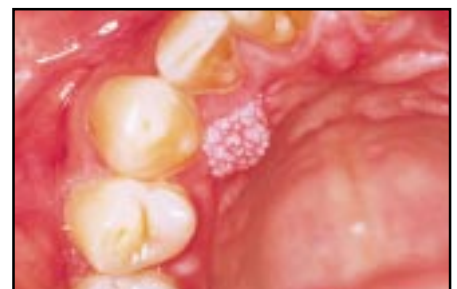**Syphilitic Leukoplakia**

**Aetiology**

Leukoplakia was a characteristic complication of tertiary syphilis but is now rare.

**Clinical Features**

Syphilitic leukoplakias have no distinctive features, but typically affect the dorsum of the tongue and spare the margins. Lesions have an irregular outline and surface, and are usually regarded as having a high risk of malignant change and cracks. Carcinoma developing near the centre of the dorsum



**Figure 6. Papilloma.**

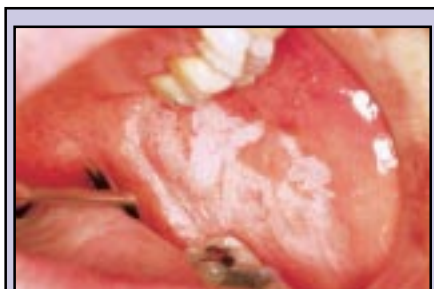

Figure 7. Homogeneous leukoplakia.

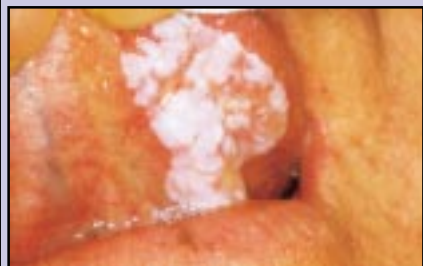

Figure 8. Verrucous leukoplakia.

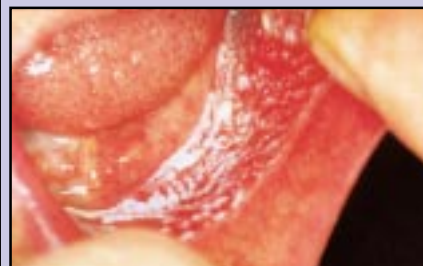

Figure 9. Speckled leukoplakia.

**Aetiology**

No aetiological factor can be identified for most persistent oral white plaques, which are thus termed idiopathic leukoplakias (Table 4). The histopathology is also highly variable, ranging from hyperkeratosis and hyperplasia to atrophy and severe dysplasia.

**Clinical Features**

Most leukoplakias are smooth white plaques (homogeneous leukoplakias); some are non-homogeneous and white and warty (proliferative verrucous leukoplakia) or mixed white and red lesions (speckled leukoplakias or erythroleukoplasia). General comments can be made including:

- Most homogeneous leukoplakias (Figure 7) show little evidence of dysplastic histological changes.
- Nodular or verrucous lesions (Figure 8) are more sinister.
- Leukoplakias which are speckled or erythroleukoplastic (Figure 9) are usually dysplastic, carcinoma *in situ*, or frank carcinomas.
- Size appears irrelevant. Small and innocent-looking white patches are as likely to show epithelial dysplasia as are large and irregular ones. Even small dysplastic lesions can be followed by carcinomas and a fatal outcome.
- Malignant change appears to be more frequent among *non*-smokers. Idiopathic leukoplakia has the highest risk of developing cancer. One of the largest studies, based on nearly 800 cases of

**Aetiology:**

- Idiopathic: most cases
- Friction
- Pipe smoking can cause 'nicotinic stomatitis' of palate
- Smokeless tobacco or betel-chewing can cause keratosis, usually of buccal sulcus.
- Candidal leukoplakias are often speckled, affect commissures and have high malignant potential
- Syphilitic leukoplakia especially affects dorsum of tongue and has high malignant potential
- 'Hairy' leukoplakia is virtually pathognomonic of HIV infection and has no malignant potential

**Management:**

- Most white lesions need to be biopsied
- Treat predisposing factors
- Surgically remove small discrete lesions < 2 cm diameter
- Observe larger lesions regularly
- Consider use of retinoids

Table 4. Leukoplakia and keratosis.

histologically unspecified oral white lesions followed for an average of 12 years, showed that 2.4% underwent malignant change in 10 years and almost 5% did after 20 years. Even this low rate represents a risk of malignant change 50 to 100 times that in the normal mouth. Several other studies have shown even higher rates of malignant change; 17.5% in over 250 patients with leukoplakia followed for an average of 8 years in one study.

- Dysplastic lesions do not have any specific clinical appearance though dysplasia is most likely where erythroplasia is present.
- Malignant change appears most

of the tongue is typically a sequel to syphilitic leukoplakia.

**Management**

The specialist will usually undertake treatment with antibiotics.

**NON-INFECTIVE LESIONS**

Lichen planus and lupus erythematosus were both discussed fully in the third article in this series: readers should refer to this for more detail.

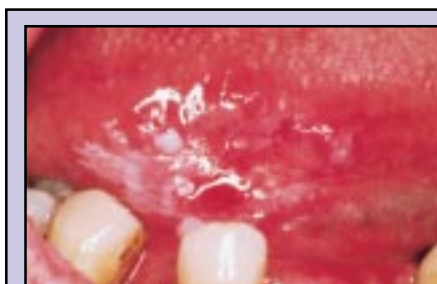**NEOPLASTIC AND POSSIBLY PRENEOPLASTIC LESIONS**

**Idiopathic (Including Dysplastic) Leukoplakia**

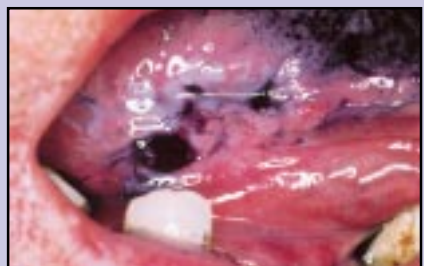Leukoplakias are relatively common white patches that cannot be wiped off the mucosa. They are seen mainly in older adults, especially men.

Dental surgeon	Ancillary staff, hygienist, nurse
Understand disease and its management in order to extend education of, and to reassure, patient	Understand disease and its management in order to extend education of, and to reassure, patient
Make diagnosis and arrange biopsy or specialist referral if there is potential malignancy	Observe lesion regularly
Observe lesion regularly	
Oral health care; in particular to avoid causes of irritation	Alert dental surgeon to any changes, or possible adverse effects of treatment
Encourage patient to stop tobacco habit	
Oral health education of patient	

Table 5. Role of members of the dental clinical team in the management of a patient with keratosis.



**Figure 10.** Leukoplakia before toluidine blue staining.



**Figure 11.** Leukoplakia after toluidine blue staining.

self-mutilation is seen in psychiatric disorders, mental handicap or some rare syndromes.

**Clinical Features**

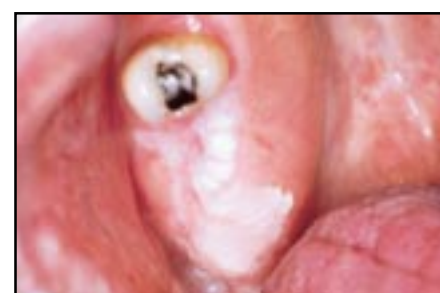In the early stages the patches are pale and translucent, but later become dense and white, sometimes with a rough surface. They are not uncommonly seen on edentulous ridges, especially in the partially dentate (Figure 12), and then presumably caused by the friction from mastication. Habitual cheek-biting causes red and white lesions with a rough surface, invariably restricted to the lower labial mucosa and/or buccal mucosa along the occlusal line (Figure 13).

**Diagnosis and Management**

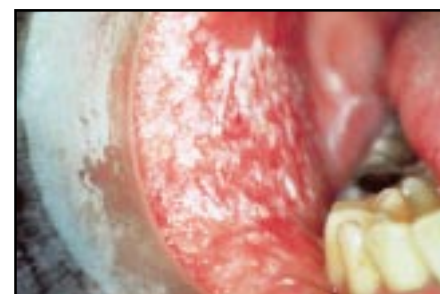The diagnosis is clinical. Frictional keratosis is completely benign, and there is no evidence that continued minor trauma alone has any carcinogenic potential. Apart from removing irritants and ceasing habits therefore, no active treatment is required.

**Tobacco-related Keratoses**

Figure 14 shows a stomatitic lesion caused by exposure to tobacco. Smoker's keratosis will be discussed in detail in a later article. Snuff dippers' keratosis and other smokeless tobacco lesions are described here.



**Figure 12.** Frictional keratosis.



**Figure 13.** Frictional keratosis.

frequently in severely dysplastic lesions. Because of the rarity of dysplastic oral lesions only a few studies, all on a small scale, have followed their progress for adequate periods. In a study of 45 patients with oral dysplastic lesions followed for up to 8 years, about 11% underwent malignant change in this period but up to 30% of them regressed or even disappeared spontaneously. It is therefore not possible to prognosticate solely on the basis of the histopathological changes. The histological assessment of oral epithelial dysplasia is also notoriously unreliable; in one study, pathologists in nearly 20% of cases could not confirm their own earlier diagnoses of dysplasia or its absence. An additional (and serious) problem is that, apart from the subjective nature of the histological assessment, there is no certainty that any biopsy specimen is representative of the whole lesion.

**Management**

The management of leukoplakias is far from satisfactory and there are no large trials that offer guidance as to the most reliable form of treatment. In view of the potential for malignant change it would seem reasonable to seek the opinion of a specialist at an early stage and if there are any changes—especially the

appearance of a swelling, induration or ulceration (Table 5).

At an early stage, an oral biopsy to look for dysplasia or worse is indicated, though of course the area biopsied may not be representative of the whole lesion. Selecting the most appropriate area to biopsy is not easy; guidance can be obtained by selecting any red area, or using a vital stain such as toluidine blue (Figures 10 and 11).

Certainly, any causal factor should be corrected where possible. Some experts remove these lesions surgically with scalpel or laser. In a few centres photodynamic therapy is employed; in this the patient is given a chemical which localizes in the leukoplakia and can be activated by shining a laser beam on the lesion to destroy the pathological tissue. Cryoprobe is now rarely used because of the possible aggravation of dysplasia and the lack of a histopathological specimen. The patient should be kept fully informed about the condition (Table 6) and followed regularly at 3- to 6-month intervals.

Retinoids are currently being investigated as a possible treatment modality; they appear very effective but can have severe adverse effects (such as teratogenicity and decreased liver function), and their beneficial effect appears to last only during the treatment.

**Frictional Keratosis and Cheek-Biting**

**Aetiology**

Frictional keratosis is caused by prolonged mild irritation by a sharp tooth, dentures, mastication or cheek-biting. Cheek-biting (morsicatio buccarum) is most prevalent in anxious females, especially those with other psychologically related disorders. Rarely,

- This is an uncommon condition
- Sometimes it is caused by friction or tobacco
- It is not inherited
- It is not known to be infectious
- In a very small number, and after years, it may lead to a tumour. You should get yourself checked regularly.
- Blood tests and biopsy may be required
- There is no universally agreed management and this can be by simple observation, drugs, or surgery. You should avoid alcohol or tobacco in future.

**Table 6.** Patient information sheet; keratosis (leukoplakia).

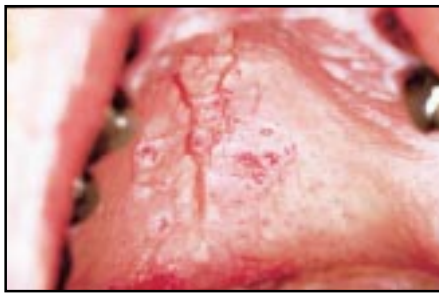

Figure 14. *Stomatitis nicotina*.

**Aetiology**

Tobacco-chewing or snuff-dipping (holding flavoured tobacco powder in the oral sulcus or vestibule) causes white hyperkeratotic lesions in up to 20% of users. Oral snuff appears to cause more severe clinical changes than does tobacco-chewing but dysplasia is more likely in tobacco chewers. Snuff-dipping is associated predominantly with verrucous keratoses, which can occasionally progress to verrucous carcinoma, but only after several decades of snuff use.

**Clinical Features**

There is typically a white lesion in the buccal sulcus, and a high proportion of the tumours are seen in the buccal mucosa/vestibule.

**Diagnosis and Management**

The diagnosis is usually obvious from the habit. Snuff dippers' lesions will resolve on stopping the habit even after 25 years of use.

**Sublingual Keratosis**

**Aetiology**

The aetiology for this condition is unknown.

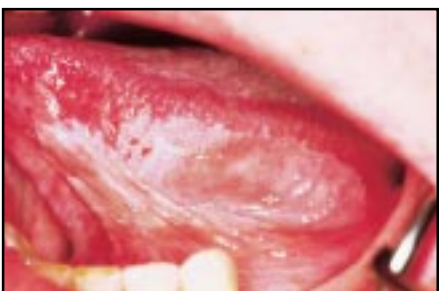

Figure 15. *Sublingual keratosis*.

**Clinical Features**

Sublingual keratosis is a soft white plaque in the sublingual region with a wrinkled surface, an irregular but well defined outline and sometimes a butterfly shape. The plaque typically extends from the anterior floor of the mouth onto the undersurface of the tongue (Figure 15).

This lesion was formerly categorized as a benign epithelial naevus. However, malignant change has been associated in 24% of one series of about 30 cases, although this high risk of malignant change has not been widely confirmed.

**Diagnosis and Management**

Diagnosis is clinical but, for the above reasons, biopsy may be indicated. A specialist opinion may be warranted. Opinions vary as to whether the lesion should be left undisturbed or removed surgically by scalpel or laser.

**Speckled Leukoplakias**

This term applies to lesions consisting of white flecks or fine nodules on an atrophic erythematous base (Figure 16), which are regarded as a combination of, or transition between, leukoplakia and erythroplasia (see below). Many cases of chronic candidosis have this appearance. Speckled leukoplakias more frequently show dysplasia than do homogeneous leukoplakias, and should be seen by a specialist.

**Carcinoma**

Oral squamous cell carcinoma may present as an innocuous-looking white patch.

**Oral Submucous Fibrosis**

Submucous fibrosis (Table 7) is an uncommon condition characterized by fibrosis of the oral submucosa, and is seen virtually only in adults from the Indian subcontinent.

**Aetiology**

The disease is caused by chewing betel (areca) nut, possibly affecting copper metabolism and collagen cross-linking, or chillies.

**Clinical Features**

The oral mucosa is mainly affected. Tight vertical bands in buccal mucosa (or palate or tongue) may progress to

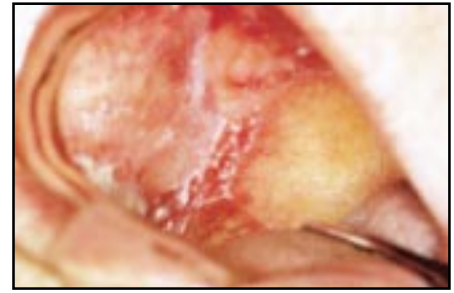

Figure 16. *Speckled leukoplakia*.

severely restricted oral opening. Areas appear almost white but not like leukoplakia—the mucosa is typically smooth, thin and atrophic, and the pallor is due to underlying fibrosis and ischaemia, and is symmetrically distributed. Often anaemia is present.

The epithelium may show dysplasia, and carcinoma develops in up to 7.5% of patients with submucous fibrosis within 10 years. Oesophageal involvement may occur.

**Diagnosis and Management**

The diagnosis is essentially clinical; only scleroderma and scarring from other causes are likely to confuse the diagnosis. However, biopsy and haematology may be required, particularly if dysplasia or carcinoma are suspected. A specialist opinion may be helpful.

The use of areca nut and chillies should be abandoned. Asymptomatic lesions should be observed only but symptomatic lesions are very difficult to manage. Exercises, intralesional corticosteroids, interferon and surgery have all been tried, each with limited success. Possibly penicillamine may help.

<p><b>Aetiology:</b></p> <ul style="list-style-type: none"> <li>● Use of areca nuts or chillies.</li> </ul> <p><b>Clinical features:</b></p> <ul style="list-style-type: none"> <li>● Tight vertical bands in buccal mucosa</li> <li>● Restricted oral opening</li> <li>● Malignant potential</li> </ul> <p><b>Incidence:</b></p> <ul style="list-style-type: none"> <li>● Virtually only a disease of adults from Indian subcontinent</li> </ul> <p><b>Management:</b></p> <ul style="list-style-type: none"> <li>● Clinical diagnosis</li> <li>● Stop use of areca nut, chillies</li> <li>● Asymptomatic: observe only</li> <li>● Symptomatic with restricted opening: exercises, intralesional corticosteroids, surgery.</li> </ul>
--

Table 7. *Oral submucous fibrosis*.

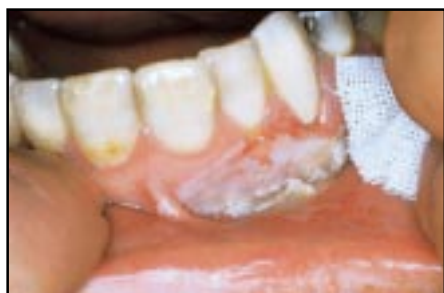

Figure 17. Burn caused by aspirin.

alongside a carious tooth (Figure 17).

### Management

Lesions are managed by stopping exposure to the chemical; the lesion is self-healing.

### Further Reading

- Axell T, Holmstrup P, Kramer IRH *et al*. International seminar on oral leukoplakia and associated lesions related to tobacco habits. *Community Dent Oral Epidemiol* 1984; **12**: 145-154.
- Burton J, Scully C. The lips. In: *Textbook of Dermatology*, 6th ed. Champion RH, Burton J, Burns DA, Breathnach SM, eds. Oxford: Blackwells, 1998; pp.3125-3148.
- Daley TD. Common acanthotic and keratotic lesions of the oral mucosa: a review. *J Can Dent Assoc* 1990; **56**: 407-409.
- Eveson JW, Scully C. *Colour Atlas of Oral Pathology*. London: Mosby-Wolfe, 1995
- Garlick JA, Taichman LB. Human papillomavirus infection of the oral mucosa. *Am J Dermatopathol* 1991; **13**: 386-395.
- Jones JH, Mason DK. *Oral Manifestations of Systemic Disease*, 2nd ed. London: Baillière Tindall, 1980
- Millard HD, Mason DK (eds). *Perspectives on 1993 World Workshop on Oral Medicine*. Michigan: University of Michigan, 1995.
- Odds FC. Candida infections: an overview. *CRC Crit Rev Microbiol* 1987; **15**: 1-5.
- Porter S, Haria S, Scully C *et al*. Chronic candidiasis, enamel hypoplasia and pigmentary anomalies. *Oral Surg Oral Med Oral Pathol* 1992; **73**: 312-314.
- Scully C. *Handbook of Oral Diseases*. London: Martin Dunitz, 1999.

- Scully C, Cawson RA. *Medical Problems in Dentistry*, 4th ed. Oxford: Butterworth-Heinemann, 1998.
- Scully C, Flint S, Porter S. *Oral Diseases*. London: Martin Dunitz, 1996.
- Scully C, Welbury R. *Colour Atlas of Oral Disease in Children and Adolescents*. London: Mosby-Wolfe, 1994.
- Scully C. The pathology of orofacial disease. In: Barnes IE, Walls AWG, eds. *Gerodontology*. Oxford: Wright, 1994; pp.29-41.
- Scully C, Porter SR. Oral mucosal disease: a decade of new entities, aetiologies and associations. *Int Dent J* 1994; **44**: 33-43.
- Scully C. Diagnosis and diagnostic procedures: general and soft tissue diagnosis. In: *Pathways in Practice*. London: Faculty of General Dental Practice, Royal College of Surgeons of England, 1993; pp.25-33.
- Scully C. Inflammatory disorders of the oral mucosa. In: English GM, ed. *Otolaryngology*. Philadelphia: Lippincott, 1993; pp.1-28.
- Scully C. Prevention of oral mucosal disease. In: Murray JJ, ed. *Prevention of Oral and Dental Disease*, 3rd ed. Oxford: Oxford University Press, 1995; pp.160-172.
- Scully C. The oral cavity. In: Champion RH, Burton J, Burns DA, Breathnach SM, eds. *Textbook of Dermatology*, 6th ed. Oxford: Blackwells, 1998; pp.3047-3124.
- Scully C, El-Kabir M, Samaranyake LP. Candida and oral candidosis. *Crit Rev Oral Biol Med* 1994; **5**: 124-158.
- Shklar G. Oral leukoplakia. *N Engl J Med* 1986; **315**: 1544-1545.
- World Health Organization Collaborating Reference Centre for Oral Precancerous Lesions. Definition of leukoplakia and related lesions: an aid to studies on oral precancer. *Oral Surg* 1985; **14**: 559.

## OTHER LESIONS

### Chemical burns

#### Aetiology

Various chemicals or drugs, notably aspirin put in the buccal sulcus to try to relieve toothache, may cause burns. Use of mouthwashes or the accidental ingestion of corrosive fluids may cause similar but more widespread lesions.

#### Clinical Features

Burns manifest as a white lesion with sloughing mucosa. Those caused by aspirin are localized usually to buccal sulcus and adjacent buccal mucosa, often

## Book Review

**Imaging in Esthetic Dentistry.** By C. E. Goldstein, R. E. Goldstein and D. A. Garber. Quintessence Publishing Co. Ltd., New Malden, 1998. (188pp., £55).

This richly illustrated book is the first to cover computer-aided dental imaging, the latest aid to planning aesthetic dentistry. Dental video cameras are commonly employed to demonstrate defects and oral disease, but are rarely used to their full potential. The book describes how to manipulate images from these cameras using a computer to model possible treatment outcomes. The authors have an international reputation for their previous books on changing smiles, laminate veneers and aesthetic inlays. Their clear and concise style is maintained in this book which is well supported with colour figures on almost

every page. The book begins by exploring the quest for beauty and describes established methods of visualizing treatment outcomes, with examples of how computer imaging enhances these techniques. Chapters 3-5 cover hardware and software. Here technical detail and jargon is sufficient without intimidating non-technical readers. Reference to particular systems and software is almost entirely generic, with guidance on important issues highlighted in bulletpoint boxes. This won't help those asking the question "What's the name of the best system?", but gives all the information needed to guide anyone purchasing an imaging system for the first time. The process of capturing and manipulating images is covered in the next six chapters. An impressive range of examples and templates is included which can be

readily adapted for use by others. Over 80% of the images were acquired by a dental hygienist showing how this task can be integrated into a team approach. The book concludes with advice on integrating imaging into practice, legal considerations and an excellent question and answer section. Peter Dawson's quote in chapter 7, "If you know where you are and you know where you are going, getting there is easy", highlights an outstanding feature of the book. The reader is guided almost effortlessly through an unfamiliar subject that offers a new and powerful tool to the modern dental practice. This book is highly recommended to anyone wishing to get more from an intra oral camera than simply using it as a 'High Tec' hand mirror.

**Simon Northeast**  
Sheffield Dental School