

ORIGINAL ARTICLE

# Reviewing the efficacy of changing prophylactic measures for the prevention of bisphosphonate related osteonecrosis of the jaws (BRONJ) in the management of oral surgery patients

C.J. Hanson, M. Macluskey & M. Skinner

Unit of Oral Surgery and Medicine, Dundee Dental School, Park Place, Dundee

**Key words:**

bisphosphonates, BRONJ, management, oral surgery, prophylaxis

**Correspondence to:**

Dr CJ Hanson  
 Unit of Oral Surgery and Medicine  
 University of Dundee Dental School  
 Park Place  
 Dundee DD1 4NH  
 Scotland  
 UK  
 Tel.: +44 138 263 5989  
 Fax: +44 138 242 5783  
 email: c.j.hanson@dundee.ac.uk

**Accepted:** 23 May 2010

doi:10.1111/j.1752-248X.2010.01085.x

**Abstract**

**Aims:** Many papers postulate treatments for established bisphosphonate related osteonecrosis of the jaws (BRONJ) or advise on ideal long-term strategies to avoid BRONJ. This article demonstrates prophylactic regimes and compares their outcomes when patients' acute symptoms demand active treatments involving bone. It assesses the efficacy of the protocols developed at Dundee Dental Hospital for prophylaxis of BRONJ in the management of patients undergoing oral surgery.

**Materials and methods:** This prospective study tracked the progress of patients who were treated in the exodontia clinics and had taken, or were taking bisphosphonates. Their consequent recovery was documented over 1, 4, 12 and 24 weeks. The prophylactic protocol followed was recorded. These data were then reviewed for healing, operator, jaw predilection and co-morbidity influences.

**Results:** In total, 25 patients were treated over the 1 year period of the study 2008–09. This amounted to 33 oral surgery treatments involving 64 extractions. Several protocols had been followed however these were grouped into: antimicrobial or chlorhexidine based protocols. In all cases, complete healing was achieved. Concomitant steroid use and increasing age were the only associated co-morbidities that increased the length of healing time. There were no direct associations of any of the other variables with healing. No prophylactic protocol was superior to another with chlorhexidine rinses proving as efficacious as any of the antibiotic regimes.

**Conclusion:** For patients taking oral bisphosphonates, simple extractions carried out with minimal trauma by graduate and supervised undergraduate operators with prophylactic chlorhexidine rinses, heal as satisfactorily as those with antibiotic based protocols for prophylaxis.

**Clinical relevance**

The Dundee protocol on the management of those patients in whom bisphosphonate therapy has been established gives some guidance to practitioners who are daily faced with these patients who need oral surgery (OS) treatments. The finding that chlorhexidine mouthwash pre, peri- and post-operatively has been a successful method of aiding healing in oral bisphosphonates patients is encouraging for it is a simple

protocol which can be applied to the general practice situation and easy for the patient to comply with at home.

**Introduction**

As the spectre of the vagaries of antibiotic cover for rheumatic fever patients waned and consensus was achieved, so the problem of bisphosphonate related osteonecrosis of the jaws (BRONJ) waxed.

Bisphosphonates are routinely prescribed for a number of conditions including: osteoporosis and its prophylaxis; skeletal malignancies; Paget's disease and multiple myeloma. BRONJ is now a recognised sequelae for a small number of patients taking or having taken bisphosphonates who undergo OS. These bony lesions can also arise de novo within the oral cavity and have the potential to be misdiagnosed as metastatic deposits and other radiolucent pathologies. The risk of BRONJ has been recognised since 1995<sup>1</sup>; however, protocols related in the management of the condition have been varied. These oral bony lesions can arise as a result of dentoalveolar manipulations and also de novo and have the potential to be misdiagnosed as metastatic deposits and other radiolucent pathologies. The action of the bisphosphonate on bone turnover and inhibition of soft tissue regeneration by leaching from the bone have been described<sup>2,3</sup>.

Different hospitals allowed clinicians of varying experience to treat these patients<sup>4</sup>.

The American Association of Oral and Maxillofacial Surgeon (AAOMS) in 2006 labelled the pathology BRONJ and defined it as 'non-healing exposed bone in the maxillo-facial region in those patients' prescribed intravenous (IV) or oral bisphosphonates.'

The update in 2009 proposed a new ICD-9-CM code for this and reviewed the staging categories<sup>5</sup>. It attributed the codes E933.6 to oral bisphosphonates and E933.7 to IV bisphosphonates and E933.1 when associated with immunosuppressive or anti-neoplastic drugs. This grouped it with osteonecrosis and osteoradionecrosis.

Reports vary on the incidence of BRONJ ranging from 0.01–0.34%<sup>6,7</sup> with the bisphosphonate route of administration affecting the percentage of these patients likely to experience this as a post-operative phenomenon. When healing is complete, as judged by the absence of AAOMS criteria for BRONJ, it places the patient back into the 'at risk' category no matter what has developed during the healing phase<sup>8</sup>.

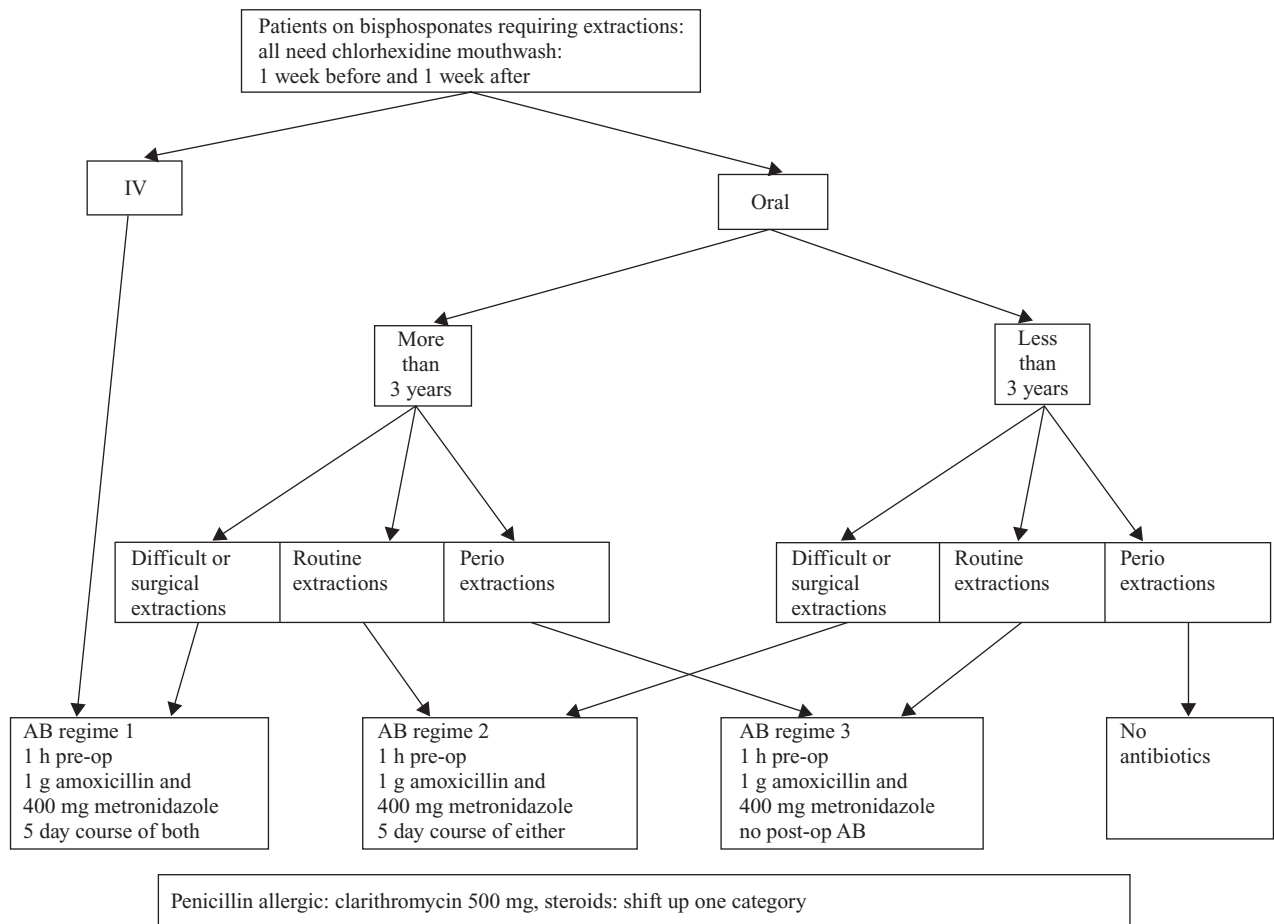


Figure 1 Initial Dundee Dental Hospital flow chart for BRONJ prophylaxis.

In Dundee, using AAOMS staging criteria<sup>9</sup> all bisphosphonate patients were classified as 'at risk' before any procedure was carried out and so prophylaxis was initiated. A list of bisphosphonate drugs was drawn up and prominently displayed in all surgical bays in the OS department and within the dental Accident and Emergency department. A flow chart for a prophylactic protocol against BRONJ was developed by a group of Consultants in the Oral Surgery and Oral Medicine units of the hospital (Fig. 1).

Clinically, it was apparent that the protocols were not followed and a number of different regimes were adopted. Given this and that the American Dental Association panel recommending that antibiotics were reserved for cases where the treatment involves significant manipulation of alveolar bone and that then antibiotics are given for 2 days before and 14 days after treatment this antibiotic prophylactic protocol was abandoned. A protocol of chlorhexidine mouthwashes 0.2% twice daily was prescribed for 1 week before extractions, peri-operatively, and for 1 week – later extended to one month – post-operatively in all cases where symptoms allowed this management.

With the need for simple global unified prophylactic regimes for any universal pathology advised<sup>10</sup>, the aim of this study was to review the outcomes of these changing regimes and develop a simple single prophylaxis.

## Materials and method

The study commenced in March 2008 and prospectively recruited patients over a 1-year period. The criteria for patient inclusion into the study were; patients who required an OS procedure and who had been prescribed bisphosphonates or were currently prescribed bisphosphonates<sup>8</sup>.

The wall list helped to alert patients that, should they be taking such drugs, they needed to inform the clinicians. They were also directly questioned on present and past prescriptions.

A chart for the collection of all OS bisphosphonate patients' hospital identification number was left in all the surgical bays. They were then tracked over the ensuing months.

Tracked parameters

- Age
- Male or female
- Which bisphosphonate was prescribed
- Duration of use of the drug
- Dose
- Morbidity for which bisphosphonate was prescribed
- Co-morbidity – pathology and pharmacology

- Which protocol had been followed
- Local anaesthetic used
- Tooth extracted
- Seniority of the prime operator
- Soft tissue and bony healing judged by the AAOMS staging guidelines<sup>9</sup>

The patients were warned of the long-term problems of extraction having taken bisphosphonates.

The patients were seen on the undergraduate exodontia clinic and were treated by supervised undergraduates of all years and by both junior and senior staff.

The local anaesthetic used was 2% lidocaine with 1 : 80 000 adrenaline. This was used according to manufacturer's protocol. (Septodont®, Saint Mair-de-Fosses, France). Merck (Merck & Co. Inc., New Jersey, US) guidelines state that when using lidocaine for treatment of patient with bisphosphonate exposure, there is 'no information available to require special precautions'<sup>11</sup>.

Post-operative antibiotics regime were explained; instructions on how to manage the wound were given verbally and in written form and in addition to these, the special instructions on the twice daily use of 10 mL of chlorhexidine 0.2% mouth washes before food.

Those patients considered to be at risk were then reviewed at 1 week for a routine post-operative review. Further intermittent reviews were carried out at what was decided were intervals that could be accommodated by the patients and would allow timely detection of any asymptomatic BRONJ stages, to wit, 4, 12, and a 24 weeks review, when clinically bone healing and remodelling would have been expected to have been established.

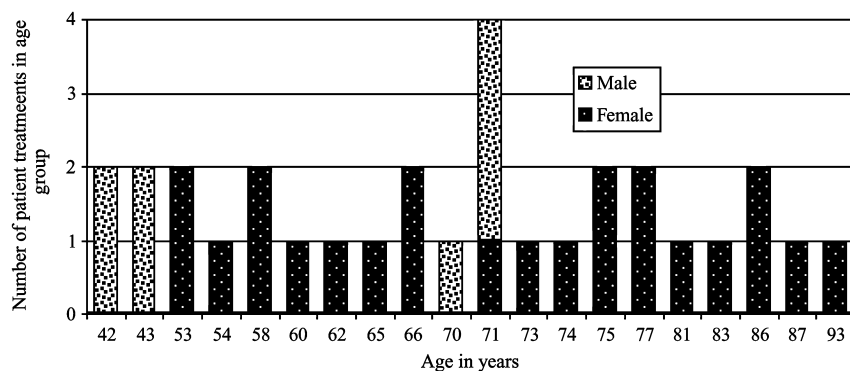
As no radiographic investigation was planned to establish the changes in the socket architecture, healing was judged by negative values, i.e. the lack of signs and symptoms that are the AAOMS criteria for BRONJ, rather than any positive radiographic indicators for bony healing and remodelling.

Complete healing was judged by:

- soft tissue coverage complete;
- no sinus, redness or swelling;
- no exposed bone, no sequester;
- pain free and
- no other signs or symptoms.

## Results

No patients refused extraction after explanation of possibility of BRONJ. Initially, 25 patients who were taking oral bisphosphonates were recorded as treated



**Figure 2** Thirty-one patient treatments tabulated by age and sex.

in the Oral Surgery Department in the year, 1st March 2008–28th February 2009; two patients died before the completion of the study.

Of the 23 patients, there were 31 patient OS treatments, a gender distribution of 3F : 1M and an age range of 42–93 years (Fig. 2).

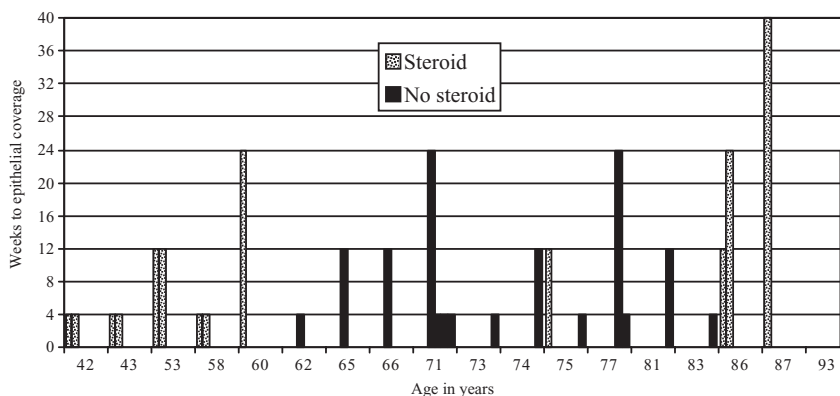
There were two soft tissue excision biopsies where the site had a potential for periosteal involvement and these were therefore included in this study as they were considered to be at risk of BRONJ.

Within the 31 OS treatments, the most commonly prescribed bisphosphonate was alendronic acid. Fifty-four per cent (17 patients) of females and 16% (5 patients) of males took this; 10% (3 patients) of both females and males took risedronate sodium and 10% (3 patients) of females took ibandronic acid but there was no association with the potency of the drug and healing time<sup>9</sup>. The most common morbidity for which it was prescribed was osteoporosis. This was from several modalities – inhaled steroid, oral steroid use for arthritides and for post-menopausal prophylaxis. Co-morbidities included asthmatics/chronic obstructive pulmonary disease 29% (9 patients), smoking 45% (14 patients), patients using anti-hypertensives 61% (19 patients) and a further 6% (2 patients) where the co-morbidity was unrecorded.

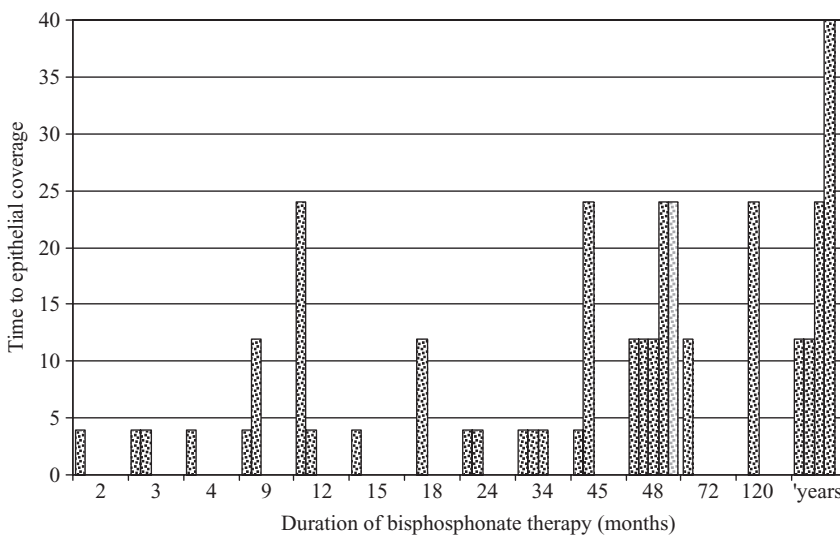
It readily became apparent that the protocol was not understood and/or followed. With changing staff populations and the protocol changing three times, the guidelines were not rigidly adhered to. Several individualised prophylactic measures had been instituted, and in total, seven different prophylactic protocols were found and arbitrarily numbered 1–7 (Table 2). Due to the very small numbers in each protocol a comparison was made between: antimicrobial (11 patients) or chlorhexidene based (22 patients) protocols.

**Table 2** Recorded prophylactic protocols for Dundee bisphosphonate patients

Prophylaxis	Protocols Antimicrobial group	Number in group – 11
1	3 g Amoxicillin 1 h preoperatively	11
2	3 g Amoxicillin oral 1 h pre-operatively 250 mg three times a day (tds) for 5 days post-operatively	
3	1 g Amoxicillin + 400 mg Metronidazole pre-operatively either at 250/200 mg 5 days chlorhexidine 0.2% mouth wash 10 mL twice daily (b.d.) for 1 week preoperatively; 10 mL peri-operatively and 10 mL b.d. 1 week post-operatively	
4	1 g Amoxicillin + 400 mg Metronidazole pre-operatively and Amoxicillin 250 mg tds for 5 days post-operatively chlorhexidine 0.2% mouth wash 10 mL b.d. pre-operatively, 10 mL peri-operatively and 10 mL b.d. for 2 weeks post-operatively	
	Chlorhexidene group	<b>Number in group – 22</b>
5	Chlorhexidine 0.2% mouth wash 10 mL b.d. for 1 week pre-operatively, 10 mL peri-operative and 10 mL b.d. 1 week post-operatively	22
6	Chlorhexidine 0.2% mouth wash 10 mL b.d. for 1 week pre-operatively 10 mL peri-operatively and 10 mL b.d. 1 month post-operatively	
7	Chlorhexidine 0.2% mouth wash 10 mL peri-operatively and 10 mL b.d. 1 month post-operatively (acute unplanned cases)	



**Figure 3** Time to epithelial coverage tabulated against age and concomitant steroid therapy (28 patient oral surgery treatments).



**Figure 4** Time to epithelial coverage and duration of bisphosphonate therapy (28 patient OS treatments).

Of this cohort, three patients wished to be reviewed by their general dental practitioners. These patients having one OS treatment episode each, left 28 OS treatments to be reviewed in the department.

The age of the patient did appear to affect the speed of healing, although the co-morbidity of steroid administration alone did not. However, in combination, it produced the single most protracted healing event of the series (Fig. 3). No association was found between time to epithelialisation and duration of bisphosphonate therapy (Fig. 4). No other co-morbidities were identified as delaying healing. There was no association between rate of healing and the experience of the operator.

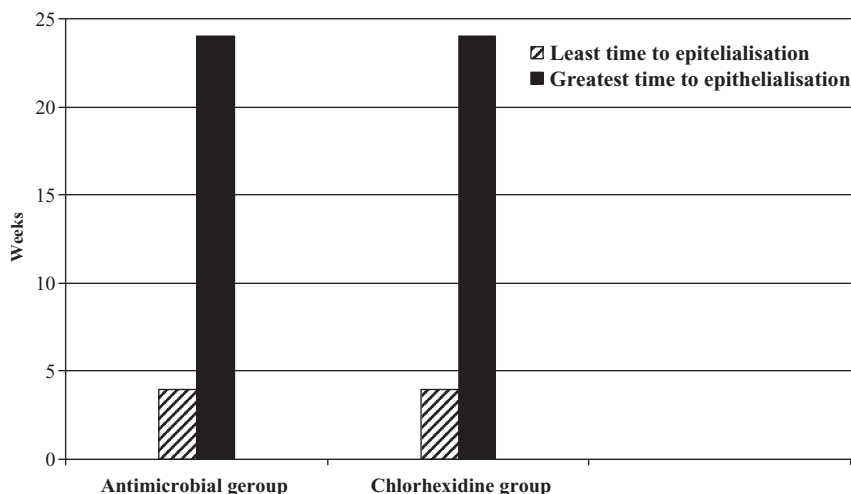
In total 64 teeth were removed. There was no associated difference in the healing between mandible and maxilla, with a ratio of 2 : 1, in this series (Table 1).

There were no repeated incidences of any of the other variables with delayed healing. Thirty-six per cent (10 patients) took 1 month for soft tissue cover-

**Table 1** Allocation of single and multi rooted teeth extracted

	Multi rooted	Single rooted
Mandibular	12	30
Maxillary	9	13

age, 39% (11 patients) up to 4 months and 21% (6 patients) had healed by the 6 month review. Four per cent (one patient) fell outside the review timing; an 87-year-old female osteoporotic patient with stage 2 BRONJ, that is, exposed/necrotic bone in patients with pain and clinical evidence of infection, who had been taking oral alendronate and steroids for over 5 years. Her healing ran a protracted course with five courses of antibiotics with final resolution after 10 months when she became sign and symptom free. The two soft tissue biopsy wounds healed without event. Although the timing of the reviews fell outside the control of the protocol of the study, so they were not included in the 28 patient episode reviews, the



**Figure 5** Comparison of time to epithelialisation between antimicrobial and chlorhexidine groups.

three patients who were reviewed by their practitioners healed successfully.

## Discussion

Globally, an increasing number of patients are taking oral bisphosphonates. For Fosamax® (Merck & Co. Inc., New Jersey, US) alone there were 18.6 million in USA in 2001 and 22 million in 2003<sup>12</sup> rising to 23 million by 2007, and 2.3 million in Australia in 2003 rising to 2.5 million in 2004<sup>7</sup>.

Information on Fosamax® used in Australia and the incidence of BRONJ has been reported. A survey form was sent to all of the Australian members of the Australian and New Zealand Association of Oral and Maxillofacial Surgeons requesting cases that they had identified as BRONJ in 2004 and 2005. The definition of BRONJ for the survey was an area of exposed bone in the jawbones that failed to heal within 6 weeks in patients taking bisphosphonates for bone disease. The frequency of BRONJ in osteoporotic patients mainly on weekly oral alendronate was 1 in 2260 to 1 in 8470 (0.01% to 0.04%) patients. If extractions were carried out, the calculated frequency was 1 in 296 to 1 in 1130 (0.09% to 0.34%) patients. The minimum values in these cases were determined from the survey whereas the maximum values were obtained from extrapolation to the entire South Australian survey data. This sample was much smaller and gives a higher incidence judged by the Australian criteria, 50% of patients in this sample took 12 or more weeks to epithelial coverage.

In a 1-year period, only a small number of patients presented requiring extractions who were exposed to oral bisphosphonates. The findings have to be interpreted with this caveat in mind. However, those patients

who had been prescribed any of the prophylactic antimicrobials showed no advantages in the healing phase over those using chlorhexidine alone (Fig. 5). This suggests that there is no indication to routinely prescribe antimicrobials as a prophylactic measure in this group of patients. They do not address the underlying pathology of the lesions and it is questionable that they would prevent infections of the wounds in all cases.

There were no patients in the chlorhexidine group in this study with refractory BRONJ and the use of protocols 6 and 7 (Table 2) is now established practice in the department.

Developing these protocols for the oral surgical treatment of these patients can be justified. This study suggests that

- For patients not in pain, a week prior to their OS treatment a chlorhexidine 0.2% mouth wash 10 mL (b.d.) daily before food, a 10 mL rinse peri-operatively and 10 mL b.d. 1 month post-operatively can be used to promote healing.
- For those patients in acute pain who cannot accommodate longer preoperative prophylaxis, this can be curtailed to the peri- and post-operative regimes.
- Simple extractions carefully carried out by clinicians, of all skill levels, healed satisfactorily.
- Post-operative monitoring of healing with intermittent review over 6 months seems to be a realistic time scale.
- Extractions, performed with minimal trauma, can be successfully carried out by supervised under and post-graduates at all levels of training.
- The mucosa over these healing sockets was very thin and the sockets did not remodel leaving irregular contours. It would seem imprudent to place a denture in these circumstances.

The need to ascertain a possible cost effective prophylaxis regime against BRONJ development after OS is paramount. The drug has a large financial impact on the cost of treating the morbidity associated with bone fragility and morbidity: benefit must be established with respect to BRONJ<sup>13,14</sup>.

This study did not include any patients taking oral bisphosphonates who had dental implants placed because no such patients came through the department. There is some evidence to suggest that oral bisphosphonates do not appear to significantly affect implant success<sup>14,15</sup>. Another study revealed that the development of BRONJ associated with dental implants is a late complication and that it is usually not related to the OS<sup>16</sup>. However, it is not clear whether these studies used a prophylactic regime that was antimicrobial based. Current evidence recommends the use of a single dose of antimicrobial pre-operatively for dental implant placement<sup>17</sup>. No reports were found of randomised controlled trials investigating the use of antimicrobials for patients taking bisphosphonates who had dental implants placed. Further research into this area is required.

## Acknowledgements

The authors would like to state that there were no conflicts of interest in this work and no funding was secured to support this work.

## References

1. Starck WJ, Epker BN. Failure of osseointegrated dental implants after diphosphonate therapy for osteoporosis: a case report. *Int J Oral Maxillofac Implants* 1995;10: 74–8.
2. Ruggiero SL, Drew SJ. Osteonecrosis of the jaws and bisphosphonate therapy. *J Dent Res* 2007;86:1013–21.
3. Reida IR BM, Grey AB. Is bisphosphonate-associated osteonecrosis of the jaw caused by soft tissue toxicity? *J Bone* 2007;41: 318–20.
4. Mcleod NMH DB, Brennan PA. Management of patients at risk of bisphosphonate osteonecrosis in maxillofacial surgery units in the UK. *The Surgeon J RCSEd J RCSI* 2009;7:18–23.
5. Ruggiero SL TBD, Assael LA, Landesberg R, Marx RE, Mehrotra B. American Association of Oral and Maxillofacial Surgeons position paper on bisphosphonate-related osteonecrosis of the jaws – 2009 update. *J Oral Maxillofac Surg* 2009; Division of Oral and Maxillofacial Surgery, Stony Brook School of Dental Medicine, Long Island Jewish Medical Center, New Hyde Park, NY, USA; 67(5 Suppl.): 2–12.
6. American Dental Association Council on Scientific Affairs. Dental management of patients receiving oral bisphosphonate therapy: expert panel recommendations. *J Am Dent Assoc* 2006;137:1144–50.
7. Sambrook P, Oliver I, Goss A. Bisphosphonates and osteonecrosis of the jaw. *Aust Fam Physician* 2006;35:801–3.
8. Zahrowski JJ. Comment on the American Association of Oral and Maxillofacial Surgeons statement on bisphosphonates. *J Oral Maxillofac Surg* 2007;65:1440–1.
9. Ruggiero SL, Dodson TB, Assael LA, Landesberg R, Marx RE, Mehrotra B. Advisory Task Force on Bisphosphonate-Related Osteonecrosis of the Jaws, American Association of Oral and Maxillofacial Surgeons position paper on bisphosphonate-related osteonecrosis of the jaws. *J Oral Maxillofac Surg* 2007;65:369–76.
10. Chate R. An infective endocarditis audit illustrates why dental quidlines in general need to be kept clear, simple and unambiguous. *Br Dent J* 2008;205:331–35.
11. Lexi-Comp.com, Alendronate, in *The Merck Manuals Online Medical Library*, Merck & Co Inc, editors. 2008. Available at: <http://www.merck.com/mmpe/lexicomp/alendronate.html#N1BA03> (accessed 4 July 2009).
12. Sachs HC. One year post exclusivity adverse event review: Alendronate editor. Pediatric Advisory Committee – Division of Pediatric Drug Development, Meeting; 15th September. 2004; Center for Drug Evaluation and Research Advisory Committee Conference Room, rm. 1066, 5630 Fishers Lane, Rockville, MD: Pub Food and Drug Administration HHS; <http://www.fda.gov/ohrms/dockets/ac/acmenu.htm> (accessed 16 June 2010).
13. Body JJ. Bisphosphonate safety and tolerability. *Oncologist* 2005;10:317; author reply 318–9.
14. Body JJ. Effectiveness and cost of bisphosphonate therapy in tumor bone disease. *Cancer* 2003; 97(3 Suppl.):859–65.
15. Bell BM, Bell RE. Oral bisphosphonates and dental implants: A retrospective study. *J Oral Maxillofac Surg* 2008;66:1022–42.
16. Grant BT, Amenedo C, Freeman K, *et al.* Outcomes of placing dental implants in patients taking oral bisphosphonates: A review of 115 cases. *J Oral Maxillofac Surg* 2008;66:223–30.
17. Lazarovici TS, Yahalom R, Taicher S, Schwartz-Arad D, Peleg O, Yarom N. Bisphosphonate-related osteonecrosis of the jaw associated with dental implants. *J Oral Maxillofac Surg* 2010;68: 790–6.