

# Occurrence of a Pyogenic Granuloma in Relation to a Dental Implant

Ivan Dojcinovic, MD, DMD,\* Michel Richter, MD, DMD,† and Tommaso Lombardi, MD, DMD‡

Pyogenic granuloma is an inflammatory vascular hyperplasia often occurring in the oral cavity. It appears in response to various stimuli such as low-grade local irritation, trauma, or female steroid hormones. A 32-year-old man sought care for a tender and bleeding lesion of the left posterior maxillary gingiva. The intraoral examination showed an exophytic ulcerated nodule measuring 1.0 cm, related to a dental implant placed in the upper left second premolar position. Radiographic examination showed an oversized healing cap. A provisional diagnosis of reactive inflammatory hyperplasia was made, and the lesion was excised and submitted for histologic examination. On microscopy, the surgical specimen showed an ulcerated nodule consisting of a delicate connective tissue stroma containing numerous blood vessels with plump endothelial cells, intermingled with abundant polymorphonuclear lymphocytes. A diagnosis of pyogenic granuloma associated with a dental implant was made. In this case it was the result of an inappropriate choice of a healing cap, thus allowing an accumulation of dental plaque and sustained chronic inflammation of the peri-implant tissue. A conservative excision and replacement of the healing cap were sufficient for definitive treatment.

© 2010 American Association of Oral and Maxillofacial Surgeons  
*J Oral Maxillofac Surg* 68:1874-1876, 2010

Pyogenic granuloma (PG) is a reactive inflammatory hyperplasia most commonly observed on the skin and the oral mucosa of children and young adults. This tumor-like lesion appears in response to various stimuli such as chronic low-grade local irritation and traumatic injury,<sup>1</sup> as well as in pregnant women and in women taking oral contraceptives. It usually appears as a solitary ulcerated nodule that may bleed, but multiple satellite lesions have also been described. The size varies from a few millimeters to several centimeters. Microscopically, PG is characterized by a benign fibrovascular proliferation with proliferating blood vessels usually lined by plump endothelial cells. In certain cases the vessels are arranged in lobules, and these cases are designated as lobular capillary hemangiomas. The term PG is a misnomer because it does not contain pus.

---

\*Senior Resident, Clinic of Maxillofacial and Oral Surgery, Geneva University Hospitals, Geneva, Switzerland.

†Professor and Chairman, Clinic of Maxillofacial and Oral Surgery, Geneva University Hospitals, Geneva, Switzerland.

‡Associate Professor, Laboratory of Oral and Maxillofacial Pathology, Division of Stomatology, School of Dental Medicine, Faculty of Medicine, Geneva, Switzerland.

Address correspondence and reprint requests to Dr Dojcinovic: Av. du Temple 13B, 1012 Lausanne, Switzerland; e-mail: [dojcinovic@hotmail.com](mailto:dojcinovic@hotmail.com)

© 2010 American Association of Oral and Maxillofacial Surgeons  
0278-2391/10/6808-0025\$36.00/0  
doi:10.1016/j.joms.2009.06.015

We describe a case of PG related to a dental implant. To our knowledge, similar cases have not been reported.

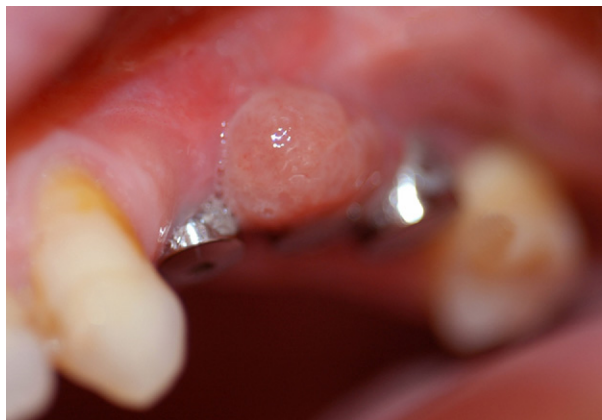## Patient and Methods

A 32-year-old man in good general health presented with a localized soft tissue mass around the closure screw of a dental implant (Fig 1). The lesion was tender and bled intermittently upon touching. His dental history showed a left maxillary sinus lift along with lateral ridge augmentation with autologous bone harvested from the iliac crest. Six months later, 3 SLA Standard Plus Straumann (Straumann Institute, Basel, Switzerland) implants (4.1 × 10-mm regular neck, 4.8 × 10-mm regular neck, and 4.8 × 10-mm wide neck) were placed in the upper left first and second premolars and upper first molar positions. After 5 months, healing caps were placed at the second stage of surgery. Four weeks later, impressions for permanent prosthetic treatment were taken.

Clinical examination showed an exophytic nodular lesion measuring 1.0 × 0.6 cm on the vestibular gingiva of the second implant placed in the upper left second premolar position.

Radiographic examination showed an oversized healing cap on the middle implant (Fig 2). There was no evidence of horizontal bone loss. In addition, the healing caps of the second and third implants were in tight contact with each other.

A provisional clinical diagnosis of inflammatory hyperplasia was made, and the patient underwent a



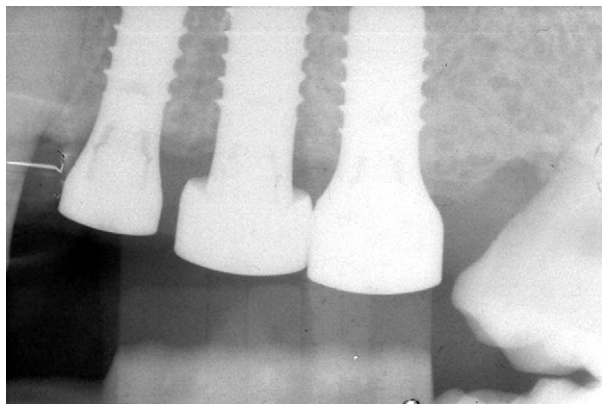
**FIGURE 1.** Erythematous ulcerated nodule located on buccal aspect of implant in the upper left second premolar position.

*Dojcinovic, Richter, and Lombardi. Pyogenic Granuloma and Dental Implant. J Oral Maxillofac Surg 2010.*

debridement flap surgery that included a complete excision of the lesion under local anesthesia, curettage of the surrounding tissues, and replacement of the oversized healing cap. The lesion was then submitted for histologic examination.

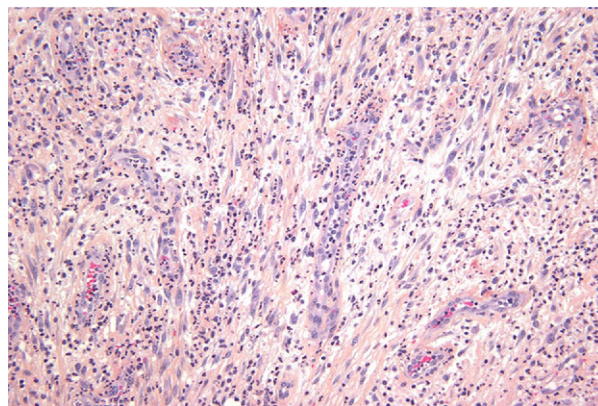
Microscopic examination showed a largely ulcerated nodule featuring an edematous granulation tissue rich in small blood vessels with prominent endothelial cells, intermingling with numerous polymorphonuclear leukocytes (Fig 3). The capillaries showed a radiating pattern extending toward the surface. The deeper part of the mass was fibrous and contained large blood vessels often surrounded by a dense chronic lymphoplasmacytic infiltrate. Besides the ulceration, the epithelium was slightly hyperplastic. These features were consistent with the diagnosis of PG.

No recurrence was seen at the follow-up visit after 18 months.



**FIGURE 2.** Radiograph showing oversized healing cap.

*Dojcinovic, Richter, and Lombardi. Pyogenic Granuloma and Dental Implant. J Oral Maxillofac Surg 2010.*



**FIGURE 3.** Edematous granulation tissue containing several capillaries intermingled with numerous neutrophils (hematoxylin-eosin stain, original magnification  $\times 20$ ).

*Dojcinovic, Richter, and Lombardi. Pyogenic Granuloma and Dental Implant. J Oral Maxillofac Surg 2010.*

## Discussion

The behavior of the soft tissues around implants is an important factor for long-term success. Peri-implant complications include dehiscence, fistula, mucositis, gingival inflammation with hyperplasia, and peri-implantitis.<sup>2</sup> These peri-implant complications are often associated with poor oral hygiene and/or a gap between components caused by loose abutment screws or framework misfits.

Gingivitis and gingival hyperplasia are the most common soft tissue complications. According to the literature, they are found in 1% to 30% of cases.<sup>2-6</sup> In some cases, they may result from an inappropriate choice of abutments, healing caps that are too short or too close to each other, the presence of dead spaces under the suprastructure, lack of attached mucosa, or faulty alignment of the implant interfering with correct oral hygiene procedures.

Cases of specific gingival hyperplasia around dental implants have been reported. These include hyperplasia induced by phenytoin medication<sup>7,8</sup> and one case of allergy to titanium abutments.<sup>9</sup> A few articles on peripheral giant cell granuloma associated with dental implants have also been published.<sup>10-13</sup>

In our case we found a PG in relation to a dental implant. A literature survey did not find any articles on PG associated with dental implants.

Hartzell was the first author to introduce the term "pyogenic granuloma."<sup>11</sup> He believed that it represented a nonspecific granulation tissue caused by a pyogenic agent.

Such lesions may be found in the oral cavity or extraorally. Intraorally, the gingiva is the most common site of involvement (about 60%-70%), followed by the lips (14%), tongue (9%), buccal mucosa (7%), and palate (2%).<sup>1,14,15</sup>

Clinically, PG is a smooth or lobulated exophytic lesion manifesting as a red nodule or mass with a pedunculated or sometimes sessile base, usually hemorrhagic and elastic in consistency. PGs are often ulcerated because of local trauma.

The etiology of PG is unknown, but PG regresses when the potential initiating stimuli are removed.<sup>16</sup> Trauma and infection have been frequently suggested as triggering factors. A hormonal cause has been suggested in some PGs because, clinically and histologically, similar lesions occur in pregnancy.<sup>17</sup> For this kind of clinical variety, the terms “pregnancy tumors” and “granuloma gravidarum” are used.

About 30% to 50% of patients with PG have a history of local trauma.<sup>18-21</sup> Poor oral local hygiene may be a precipitating factor in most of these cases.<sup>22</sup> Aguilo<sup>23</sup> and Aguilo and Bagan<sup>24</sup> reported the occurrence of PG as a result of an injury to a primary tooth, as well as 2 cases of PG in the maxillary labial mucosa, which were related to an apical fenestration of a primary incisor tooth. Milano et al<sup>25</sup> described a case of PG in relation to aberrant tooth development.

In our case the implants were stable but the inappropriate healing cap of the second implant resulted in dental plaque accumulation and thus sustained chronic inflammation of the gingival peri-implant tissues, triggering the development of a PG.

PGs are treated by a variety of methods, most commonly surgical excision and elimination of etiologic irritants (plaque, calculus, foreign materials, source of trauma).<sup>22,26</sup>

Other treatment protocols have also been proposed such as cryotherapy, chemical and electric cauterization, and the use of Nd:YAG (neodymium:yttrium-aluminum-garnet) laser and carbon dioxide laser.<sup>27</sup> Meffert et al<sup>28</sup> used the flash lamp pulsed-dye laser on granulation tissue around a dental implant.

Successful treatment with intralesional corticosteroid injections has also been documented.<sup>29</sup> After excision, recurrence is seen in up to 16% of the lesions.<sup>30</sup> This is believed to result from incomplete excision, failure to eliminate etiologic factors, or re-injury to the area. In this case re-excision is mandatory.

It is important to choose a healing cap that corresponds to the size of the implant used. An ill-fitting cap may lead to the development of a reactive gingival lesion such as PG, which in turn may jeopardize the implant survival.

## References

- Bhaskar SN, Jacoway JR: Pyogenic granuloma—Clinical features, incidence, histology, and result of treatment: Report of 242 cases. *J Oral Surg* 24:391, 1966
- Goodacre CJ, Kan JY, Rungcharassaeng K: Clinical complications of osseointegrated implants. *J Prosthet Dent* 81:537, 1999
- Tolman DE, Laney WR: Tissue-integrated prosthesis complications. *Int J Oral Maxillofac Implants* 7:477, 1992
- Wyatt CC, Zarb GA: Treatment outcomes of patients with implant-supported fixed partial prostheses. *Int J Oral Maxillofac Implants* 13:204, 1998
- Adell R, Lekholm U, Rockler B, et al: A 15-year study of osseointegrated implants in the treatment of the edentulous jaw. *Int J Oral Surg* 10:387, 1981
- Wennerberg A, Jemt T: Complications in partially edentulous implant patients: A 5-year retrospective follow-up study of 133 patients supplied with unilateral maxillary prostheses. *Clin Implant Dent Relat Res* 1:49, 1999
- Chee WW, Jansen CE: Phenytoin hyperplasia occurring in relation to titanium implants: A clinical report. *Int J Oral Maxillofac Implants* 9:107, 1994
- Bredfeldt GW: Phenytoin-induced hyperplasia found in edentulous patients. *J Am Dent Assoc* 123:61, 1992
- Mitchell DL, Synnott SA, Van Dercreek JA: Tissue reaction involving an intraoral skin graft and CP titanium abutments: A clinical report. *Int J Oral Maxillofac Implants* 5:79, 1990
- Bischof M, Nedir R, Lombardi T: Peripheral giant cell granuloma associated with a dental implant. *Int J Oral Maxillofac Implants* 19:295, 2004
- Hirshberg A, Kozlovsky A, Schwartz-Arad D, et al: Peripheral giant cell granuloma associated with dental implants. *J Periodontol* 74:1381, 2003
- Cloutier M, Charles M, Carmichael RP, et al: An analysis of peripheral giant cell granuloma associated with dental implant treatment. *Oral Surg Oral Med Oral Pathol Oral Radiol Endod* 103:618, 2006
- Scarano A, Iezzi G, Artese L, et al: Peripheral giant cell granuloma associated with a dental implant. A case report. *Minerva Stomatol* 57:529, 2008
- Laskaris G: *Color Atlas of Oral Diseases* (ed 2). New York, Thieme Medical Publishers, 1994
- Angelopoulos AP: Pyogenic granuloma of the oral cavity: Statistical analysis of its clinical features. *J Oral Surg* 29:840, 1971
- Requena L, Sanguenza OP: Cutaneous vascular proliferation. Part II. Hyperplasias and benign neoplasms. *J Am Acad Dermatol* 37:887, 1997
- Sills ES, Zegarelli DJ, Hoschander MM, et al: Clinical diagnosis and management of hormonally responsive oral pregnancy tumor (pyogenic granuloma). *J Reprod Med* 41:467, 1996
- Pilch B: *Head and Neck Surgical Pathology*. Philadelphia, PA, Lippincott Williams & Wilkins, 2001, pp 389-390
- Premalatha S, Thambiah AS: Pyogenic granuloma following the trauma of nose-boring. *Br J Dermatol* 100:455, 1979
- Naimer SA, Cohen A, Vardy D: Pyogenic granuloma of the penile shaft following circumcision. *Pediatr Dermatol* 19:39, 2002
- Leyden JJ, Master GH: Oral cavity pyogenic granuloma. *Arch Dermatol* 108:226, 1973
- Neville B, Damm D, Allen C, et al: *Oral & Maxillofacial Pathology* (ed 2). Philadelphia, PA, Saunders, 2002
- Aguilo L: Pyogenic granuloma subsequent to injury of a primary tooth. A case report. *Int J Paediatr Dent* 12:438, 2002
- Aguilo L, Bagan JV: Pyogenic granuloma subsequent to apical fenestration of a primary tooth. *J Am Dent Assoc* 133:599, 2002
- Milano M, Flaitz CM, Bennett J: Pyogenic granuloma associated with aberrant tooth development. *Tex Dent J* 118:166, 2001
- Eversole L: *Clinical Outline of Oral Pathology: Diagnosis and Treatment* (ed 3). Hamilton, BC Decker, 2002
- White JM, Chaudhry SI, Kudler JJ, et al: Nd:YAG and CO<sub>2</sub> laser therapy of oral mucosal lesions. *J Clin Laser Med Surg* 16:299, 1998
- Meffert JJ, Cagna DR, Meffert RM: Treatment of oral granulation tissue with the flashlamp pulsed dye laser. *Dermatol Surg* 24:845, 1998
- Parisi E, Glick PH, Glick M: Recurrent intraoral pyogenic granuloma with satellitosis treated with corticosteroids. *Oral Dis* 12:70, 2006
- Taira JW, Hill TL, Everett MA: Lobular capillary hemangioma (pyogenic granuloma) with satellitosis. *J Am Acad Dermatol* 27:300, 1992