

Inflammatory Implant Periapical Lesion: Etiology, Diagnosis, and Treatment—Presentation of 7 Cases

Miguel Peñarrocha-Diago, DDS, PhD,*

Araceli Boronat-Lopez, DDS,†

and Berta García-Mira, DDS, PhD‡

Purpose: To investigate implant periapical lesions, and to describe their treatment. The hypothesis of this evaluation is that implant periapical lesions are disorders of the area surrounding the apex of a dental implant, and that their etiology can be multifactorial (ie, vascular impairment, vascular ischemia, overheating of bone during drilling, and implant surface contamination). The diagnosis is based on the clinical manifestations and x-ray findings. The x-ray findings usually involve a periapical radiotransparency.

Materials and Methods: Seven patients with implant periapical lesions (3 in the upper jaw, and 4 in the mandible) after implant placement are described. All patients reported pain, and 3 suffered from inflammation. Upon percussion, the 3 nonsubmerged implants produced a dull sound, with no mobility. A panoramic x-ray study showed periapical transparencies around 5 implants, whereas in 1 case, computed tomography showed a maxillary sinus reaction. The diagnosis was acute apical peri-implantitis (nonsuppurative in 2 cases, and suppurative in 5 cases).

Results: The clinical manifestations did not subside with antibiotics. In all cases, treatment consisted of implant periapical surgery, after which the symptoms disappeared. The radiotransparencies showed progressive resolution.

Conclusion: The possibility of implant periapical lesions must be taken into account. A rapid diagnosis should be established to treat the lesions at an early stage, hence preventing the need for implant extraction.

© 2009 American Association of Oral and Maxillofacial Surgeons

J Oral Maxillofac Surg 67:168-173, 2009

In 1993, Sussman and Moss¹ introduced the concept of implant periapical pathology as an infectious-inflammatory disorder of the tissues surrounding the apex of a dental implant. The underlying causes may include vascular impairment, overheating of bone during drilling, and vascular ischemia, all of which can result in bone loss around the apex of the implant. Other etiological factors may comprise overheating of bone during drilling,² overdrilling of the site, implant surface contamination,^{3,4} pre-existing bone pathology, the presence of root remains, and implant placement

close to an infected maxillary sinus.⁵ The incidence of implant periapical lesions is very low, and almost all studies in the literature are limited to 1 or 2 cases.^{2,3,5}

We describe 7 patients with implant periapical pathology, whose treatment was provided in the form of periapical surgery. A Medline review is also presented of the literature on implant periapical lesions spanning the past 10 years.

Materials and Methods

Between 1996 and 2002, the same surgeon in the same operating room conventionally placed approximately 2,500 implants under abundant irrigation with saline solution. We documented all cases in which implant periapical surgery was performed. The criteria for performing such surgery included: 1) acute pain after implant placement that failed to respond to antibiotic treatment (amoxicillin 500 mg, 3 times a day, for 7 days); 2) absence of implant mobility; 3) dull percussion of nonsubmerged implants; and 4) presence or absence of implant periapical radiolucency. In the presence of implant mobility, non-

Received from the Faculty of Medicine and Dentistry, University of Valencia, Valencia, Spain.

*Professor of Oral Surgery.

†Associate Professor of Oral Surgery.

‡Master of Oral Surgery and Implantology.

Address correspondence and reprint requests to Dr Penarrocha-Diago: Clinicas Odontológicas, Gasco Oliag 1, 46021 Valencia, Spain; e-mail: Miguel.Penarrocha@uv.es

© 2009 American Association of Oral and Maxillofacial Surgeons

0278-2391/09/6701-0025\$34.00/0

doi:10.1016/j.joms.2007.12.022

dull percussion, or radiolucency along the longitudinal axis of the implant, peri-implant surgery was not considered.

CASE 1

A 32-year-old woman with no relevant medical history presented with a partially edentulous upper jaw. Ten days after placement of a submerged 14×4.1 mm ITI implant (Straumann, Waladent, Switzerland) in the zone of the left maxillary central incisor, she developed pain in the apical region that failed to subside with antibiotics. Periapical surgery was performed, and the course of the fixation proved favorable, allowing for implant loading after 3 months.

CASE 2

A 32-year-old woman presented with a totally edentulous lower jaw. Seven days after surgery, she developed pain in the implant periapical zone, and percussion proved dull, with identification of an apical radiolucency. Antibiotic treatment was provided, and 2 weeks after implant placement, periapical surgery was performed, allowing for implant loading after 4 months.

CASE 3

A 78-year-old woman developed pain 12 days after implant placement in the region of the right mandibular first premolar, with dull percussion. Periapical x-rays showed radiolucency in the zone of the implant apex. Antibiotics were prescribed, and periapical surgery was performed 3 weeks after the intervention. Her subsequent course proved favorable, and implant loading could be performed after 2 months.

CASE 4

A 70-year-old woman developed implant apical pain in the region of the right mandibular lateral incisor, 1 week after placement, with dull percussion and an apical radiolucent image. Antibiotic treatment proved ineffective, and periapical surgery was performed, with implant loading after 3 months.

CASE 5

A 49-year-old man with no relevant medical history developed pain and gingival swelling in the region of an implant placed 7 days previously in the zone of the left maxillary first premolar. A sinus reaction was suspected and confirmed by computed tomography. After 1 week of antibiotic treatment, periapical surgery successfully resolved the lesion, and placement of the prosthesis proved possible after 3 months.

CASE 6

A 56-year-old man presented with a totally edentulous upper jaw. Fifteen days after implant placement, he developed pain and gingival swelling. Periapical

surgery was performed after 4 weeks, with implant loading 3 months later.

CASE 7

A 60-year-old woman developed pain and gingival swelling in the region of an implant placed 10 days previously in the left mandibular lateral incisor. An x-ray study revealed a radiolucent image. The symptoms failed to subside with antibiotic treatment, and periapical surgery was performed, followed by a favorable course and implant loading after 3 months.

Peri-implant surgery was performed in 7 cases (3 in the upper jaw and 4 in the mandible). In 6 cases we used sandblasted and acid-etched (SLA) surface ITI implants (Straumann), and in one case, an Avantblast surface Defcon implant (Impladent, Senmenat, Barcelona, Spain). Four submerged and 3 nonsubmerged implants were involved.

The patients included 5 women and 2 men (age range, 32 to 78 years). In all cases, oral and radiologic examinations were performed, based on periapical and extraoral panoramic x-rays. In addition, computed axial tomographic imaging was performed in one patient with suspected maxillary sinusitis.

SURGICAL PROCEDURE

Surgery was performed under local anesthesia (4% articaine with 1:100,000 adrenalin), raising a full-thickness flap in the affected zone. A tungsten drill was used to perform the ostectomy to gain access to the implant apex, under abundant irrigation with sterile saline solution. Curettage of the inflamed tissue was performed, followed by a histologic study of the samples collected. An ultrasound tip was used to irrigate the surgical bed with sterile saline solution. When necessary, bone shavings from the surgical field or synthetic bone (Bio-Oss; Geistlich, Wolhusen, Switzerland) were placed in the bone defect. After 8 to 12 weeks, second-step surgery was performed, and prosthetic rehabilitation of the implants was carried out (Figs 1-6).

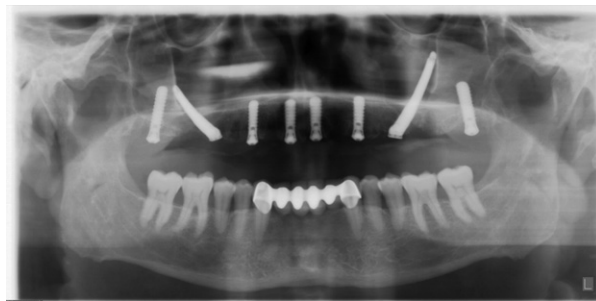

FIGURE 1. Case 6. Extraoral panoramic x-ray view after dental implant placement: 4 in the anterior sector, 2 trans-zygomatic implants, and 2 pterygoid implants.

Penarrocha-Diago, Boronat-Lopez, and García-Mira. Inflammatory Implant Periapical Lesions. J Oral Maxillofac Surg 2009.

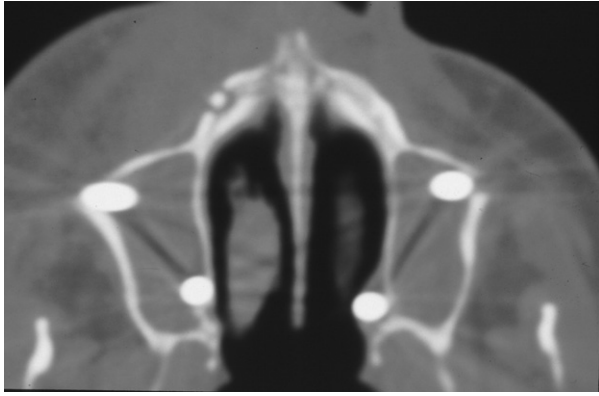


FIGURE 2. Case 6. After 15 days, the patient reported constant pain in the zone of tooth 3. Computed tomography showed loss of the vestibular layer, with the identification of an peri-implant radiolucency. The maxillary sinuses presented artifacts attributable to the trans-zygomatic implants.

Penarrocha-Diago, Boronat-Lopez, and García-Mira. Inflammatory Implant Periapical Lesions. J Oral Maxillofac Surg 2009.

Results

The patients' characteristics are summarized in [Table 1](#). Approximately 7 to 15 days after implant placement, all patients reported pain, with gingival inflammation of the affected zone in 3 cases. No fistulas were observed; no implants presented mobility; and 3 implants showed dull percussion (in 4 cases, this could not be evaluated because the implants were submerged). A radiologic study revealed radiolucency around the apex of 5 implants, and in one case, computed tomography showed a maxillary-sinus reaction.

In all cases, the diagnosis was acute apical peri-implantitis, as based on the symptoms. In 3 cases, sufficient material could be collected for a histologic study (using hematoxylin-eosin staining). An acute inflammatory infiltrate was identified in all cases.

One week after periapical surgery, the pain and inflammation had subsided. The radiolucencies gradually resolved entirely. Between 2 and 4 months later, implant loading started, and after a minimum follow-up of 1 year, all 7 implants were seen to remain functional in the mouth, with no clinical or radiologic alterations.

Discussion

Implant periapical lesions are infrequent, with an incidence of 10 cases per 3,800 implants, according to Reiser and Nevins.⁶ In our series of implant periapical lesions, the symptoms appeared 7 to 15 days after surgery, in concordance with the report of Rodríguez and Rodríguez.⁷ However, other authors^{2,8} described implant radiolucencies even months later. Despite systemic antibiotic medication, the clinical

manifestations failed to improve in our patients, and all underwent peri-implant surgery.

The diagnosis of inflammatory implant periapical lesions is based on clinical findings (pain, possible swelling, and dull percussion) and radiologic evidence, since at some stage, a radiolucent image may appear at implant periapical level, reflecting the existence of suppuration. [Table 2](#) lists 8 implant periapical lesions described by different authors.^{2,3,5,7-9} Bretz et al⁹ reported that maxillary sinusitis was associated with the implant apical zone, whereas one of our patients developed a sinusal reaction. Unlike other investigators,^{2,3,7,8} we recorded no fistulas. The appearance of a fistula probably corresponds to a more advanced phase of periapical disease (periapical abscess), and in this sense, our lesions were diagnosed and treated at an early stage of acute apical periimplantitis. Five lesions were suppurative, and 2 were nonsuppurative but not fistular.

Such periapical lesions may be secondary to contamination during instrumentation, as suggested by

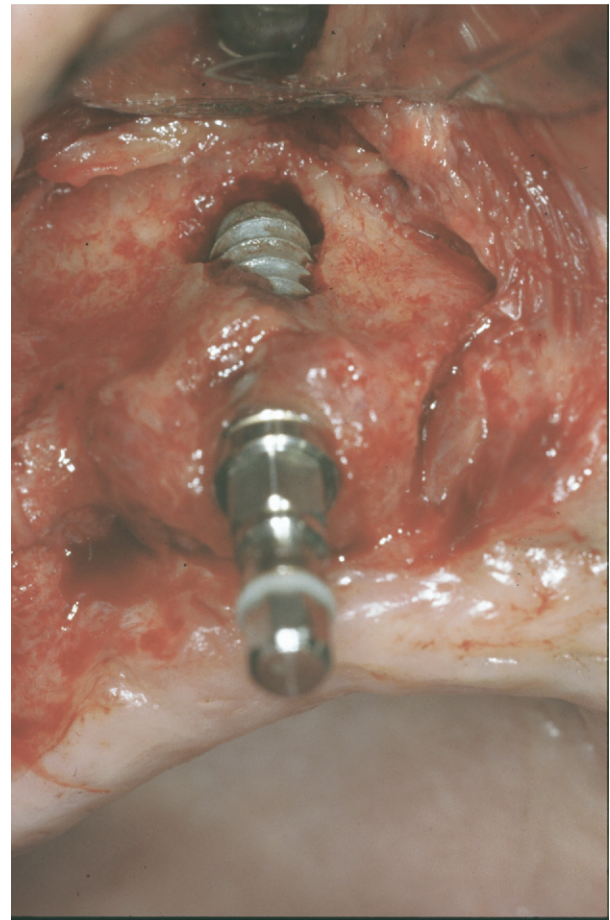


FIGURE 3. Case 6. After raising a full-thickness flap, destruction of the vestibular layer is observed in the apical zone of the implant. *Penarrocha-Diago, Boronat-Lopez, and García-Mira. Inflammatory Implant Periapical Lesions. J Oral Maxillofac Surg 2009.*

Scarano et al.⁵ According to other authors,^{2,3} these lesions result from excessive heating of bone during surgery. Ayangco and Sheridan⁸ described 3 cases of implant periapical lesions in patients with a history of endodontic treatment and failed apicoectomy before implant placement. According to these authors, despite curettage, socket cleaning, and a long waiting time, bacteria would have persisted in the bone, causing implant periapical alterations as a result. Sussman¹⁰ classified such lesions as implant-to-tooth (type I) when produced during instrumentation of the implant bed, and as tooth-to-implant (type II) when originating from apical lesions of the teeth adjacent to the implant. In our cases, there was no previous periapical pathology, and the lesions may have been a consequence of contamination of the apical region of the bed during surgery.

None of the cases responded to antibiotic therapy alone, indicating that bacteria were not the only cause of the condition, therefore necessitating surgery. In our cases, the histopathologic study identified an acute in-

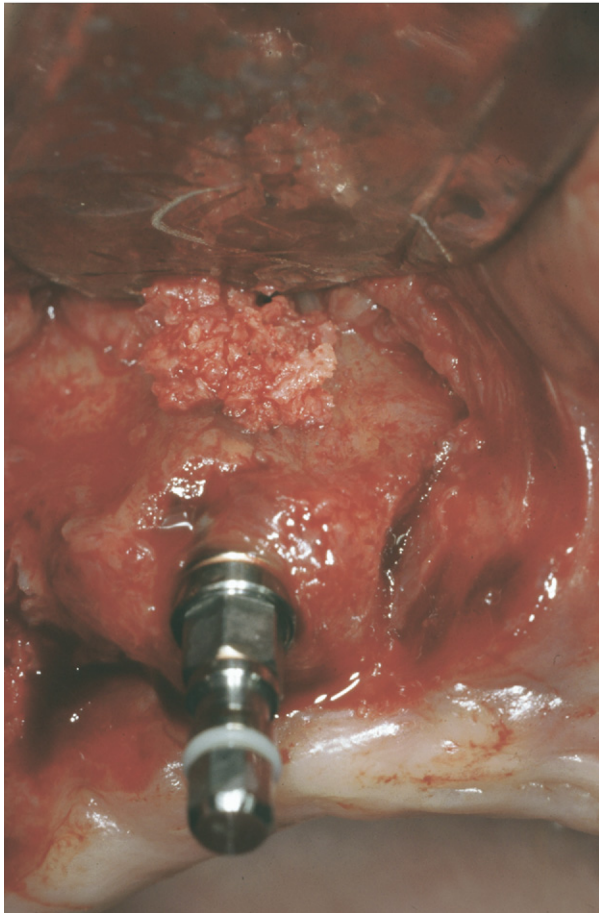


FIGURE 4. Case 6. Careful curettage of the zone was performed, with elimination of all inflammatory tissue. Bone shavings from the surgical field were placed in the bone defect.

Penarrocha-Diago, Boronat-Lopez, and García-Mira. Inflammatory Implant Periapical Lesions. J Oral Maxillofac Surg 2009.

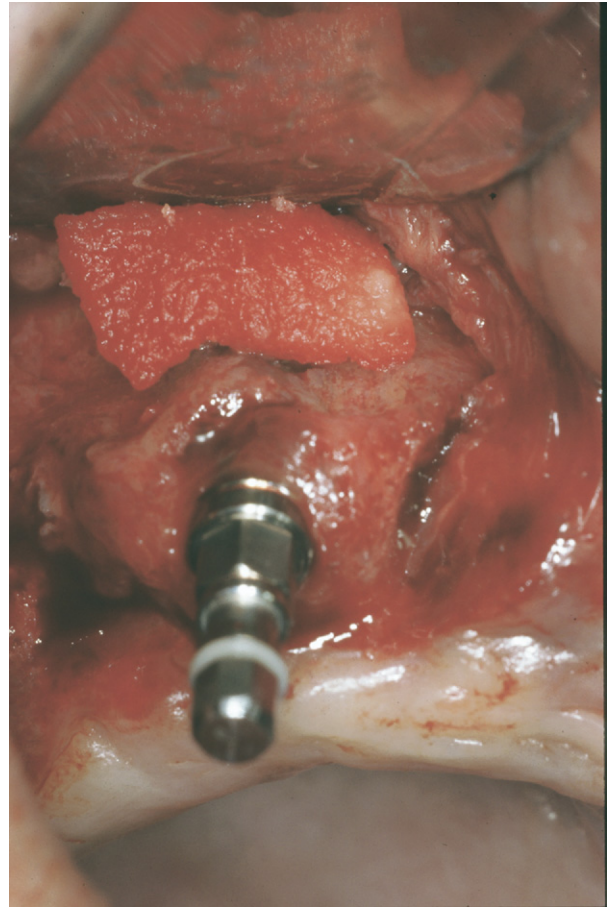


FIGURE 5. Case 6. An absorbable collagen membrane is placed on the surgical field.

Penarrocha-Diago, Boronat-Lopez, and García-Mira. Inflammatory Implant Periapical Lesions. J Oral Maxillofac Surg 2009.

flammatory infiltrate, in concordance with other investigators, eg, Piattelli et al⁵ and Balshi et al.¹¹

Bretz et al⁹ successfully performed periapical surgery with curettage and chlorhexidine irrigation to

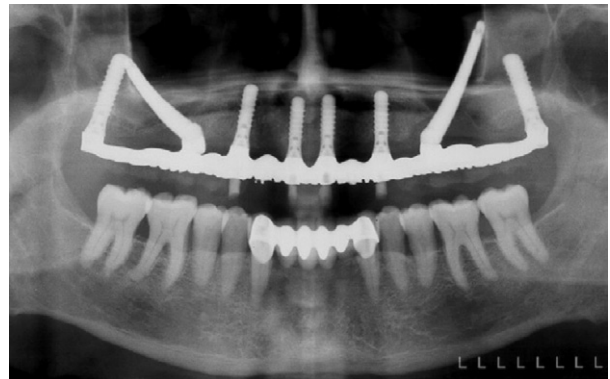

FIGURE 6. Case 6. Panoramic x-ray view after placement of the definitive screwed prostheses.

Penarrocha-Diago, Boronat-Lopez, and García-Mira. Inflammatory Implant Periapical Lesions. J Oral Maxillofac Surg 2009.

Table 1. CHARACTERISTICS OF PATIENTS WITH IMPLANT PERIAPICAL LESIONS

	Case 1	Case 2	Case 3	Case 4	Case 5	Case 6	Case 7
Age (yr)	32	32	78	70	49	56	60
Gender	F	F	F	F	M	M	F
Edentulism	Partial upper	Total	Total	Total	Partial upper	Total upper	Partial lower
Location	2.1	3.2	4.4	4.2	2.4	1.3	3.2
Implant							
Type	ITI	ITI	ITI	ITI	ITI	ITI	Defcon
Length	14 mm	14 mm	16 mm	14 mm	12 mm	12 mm	16 mm
Diameter	4.1 mm	4.1 mm	4.1 mm	4.1 mm	4.1 mm	4.1 mm	4.2 mm
Submerged	Yes	No	No	No	Yes	Yes	Yes
Time to symptoms (days)	10	7	12	7	7	15	10
Time to treatment (weeks)	4	2	3	5	3	4	3
Symptoms							
Pain	Yes	Yes	Yes	Yes	Yes	Yes	Yes
Signs							
Percussion	–	Dull	Dull	Dull	–	–	–
Mobility	–	No	No	No	–	–	–
Inflammation	No	No	No	No	Yes	Yes	Yes
Apical radiotransparency	No	Yes	Yes	No	Sinus reaction: CT	Yes	Yes
Treatment	Apical surgery Acute inflammatory infiltrate	Apical surgery Acute inflammatory infiltrate	Apical surgery	Apical surgery	Apical surgery Acute inflammatory infiltrate	Apical surgery	Apical surgery
Histology							
Course	+	+	+	+	+	+	+
Loading after periapical surgery (mo)	3	4	2	3	3	3	3
Control	6 years	15 months	1 year	1 year	18 months	1 year	1 year

Abbreviations: ITI, Straumann, Waladent, Switzerland; Defcon, Impladent, Senmenat, Barcelona, Spain; –, not evaluable, because implant is submerged; +, positive course; CT, computed tomography.

Penarrocha-Diago, Boronat-Lopez, and García-Mira. *Inflammatory Implant Periapical Lesions*. *J Oral Maxillofac Surg* 2009.

Table 2. STUDIES WITH IMPLANT PERIAPICAL LESIONS

Authors	Number of Implant Periapical Lesions	Implant Location	Time to Diagnosis (mo)	Pain	Fistula	Radiotransparency	Treatment	Success
Piattelli et al ²	1	Maxillary premolar	7		Yes	Yes	Implant removal	No
Piattelli et al ³	1	Mandible	5		Yes	Yes	Implant removal	No
Scarano et al ⁵	1	Premolar mandible	6	Yes	No	Yes	Implant removal	No
Rodríguez and Rodríguez ⁷	1	Mandible	8	Yes	Yes	Yes	Curettage and irrigation	Yes
Ayangco and Sheridan ⁸	3	Maxillary first premolar	18		Yes	Yes	Curettage and tetracycline	Yes
		Maxillary second premolar	9		No	Yes		
		Canine mandibular	1	Yes	No	Yes		
Bretz et al ⁹	1	Maxillary lateral incisor	6		Yes	Yes	Curettage and irrigation	Yes

Penarrocha-Diago, Boronat-Lopez, and García-Mira. *Inflammatory Implant Periapical Lesions*. *J Oral Maxillofac Surg* 2009.

treat an implant periapical lesion, with the placement of demineralized bone and a collagen membrane covering. Ayangco and Sheridan⁸ also performed periapical surgery on an implant, with the additional placement of tetracycline in the zone for 1 minute, for local disinfection. As an alternative to treatment, these authors mentioned the possibility of sectioning the implant apex in those cases where complete removal of the granular tissue is not assured, and when the location involves the maxillary sinus or nasal cavity. We performed periapical surgery, gaining access to the apex through an osteotomy window. If the vestibular bone wall was found to be intact, the inflammatory tissue was removed, and chlorhexidine irrigation was performed. Posteriorly, we introduced the implant a further 1 to 2 mm in the bone, to improve primary fixation and ensure better soft-tissue closure.

The treatment of implant periapical pathology depends on the stage of the lesion. In the case of an acute lesion (suppurative or otherwise), we perform periapical surgery with curettage and irrigation,⁸⁻¹⁰ whereas in the case of a periapical abscess affecting the bone surface or involving the loss of primary fixation, implant removal is the only management option.^{2,3,12} For this reason, Reiser and Nevins⁶ contend that implant periapical pathology treatment should be immediate, to avoid the need for extraction.

References

- Sussman HI, Moss SS: Localized osteomyelitis secondary to endodontic-implant pathosis. A case report. *J Periodontol* 64:306, 1993
- Piattelli A, Scarano A, Balleri P, et al: Clinical and histologic evaluation of an active "implant periapical lesion." A case report. *Int J Oral Maxillofac Implants* 13:713, 1998
- Piattelli A, Scarano A, Piattelli M, et al: Implant periapical lesions: Clinical, histologic and histochemical aspects. A case report. *Int J Periodont Restor Dent* 18:181, 1998
- Chaffee NR, Lowden K, Tiffée JC, et al: Periapical abscess formation and resolution adjacent to dental implants: A clinical report. *J Prosthet Dent* 85:109, 2001
- Scarano A, Di Domizio P, Petrone G, et al: Implant periapical lesion: A clinical and histologic case report. *J Oral Implantol* 26:109, 2000
- Reiser GM, Nevins M: The implant periapical lesion: Etiology, prevention and treatment. *Compend Contin Educ Dent* 16:768, 1995
- Rodríguez A, Rodríguez F: Proceso periapical implantológico. *Rev Esp Odontostomatol Implantol* 3:159, 1995
- Ayangco L, Sheridan PJ: Development and treatment of retrograde peri-implantitis involving a site with a history of failed endodontic procedures: A series of reports. *Int J Oral Maxillofac Implants* 16:412, 2001
- Bretz WA, Matuck AN, de Oliveira G, et al: Treatment of retrograde peri-implantitis: A clinical report. *Implant Dent* 6:287, 1997
- Sussman HI: Periapical implant pathology. *J Oral Implantol* 24:133, 1998
- Balshi J, Pappas E, Wolfinger J, et al: Management of an abscess around the apex of a mandibular root-form implant: Clinical report. *Implant Dent* 3:815, 1994
- Oh TJ, Yoon J, Wang HL: Management of the implant periapical lesion: A case report. *Implant Dent* 12:41, 2003