

Clinical Evaluations of Coronectomy (Intentional Partial Odontectomy) for Mandibular Third Molars Using Dental Computed Tomography: A Case-Control Study

Yuko Hatano, DDS,* Kenichi Kurita, DDS, PhD,†
Yuichiro Kuroiwa, DDS, PhD,‡ Hidemichi Yuasa, DDS, PhD,§
and Eiichiro Arijii, DDS, PhD¶

Purpose: Studies have suggested that coronectomy reduces the risk of inferior alveolar nerve injury (IANI) when a close relationship with the inferior alveolar canal is indicated on panoramic imaging. However, the relationship between the inferior alveolar canal and the root are unclear on panoramic imaging. Our aim was to compare coronectomy with traditional extraction for the treatment of mandibular third molars that had clear high IANI risks as evaluated by dental computed tomography.

Patients and Methods: We designed a case-control study of subjects with high-risk signs of IANI on panoramic images evaluated by dental computed tomography before enrollment. The 220 patients enrolled were assigned to extraction (control group, n = 118) or coronectomy (case group, n = 102).

Results: The mean follow-up time was 13 months in the extraction group and 13.5 months in the coronectomy group. Six IANIs (5%) were found in the extraction group. In the coronectomy group, 1 patient (1%) had symptoms of neurapraxia, which disappeared within 1 month. Four remaining roots had signs of postoperative infection, and the patients underwent extraction of the root. No nerve damage resulted in these patients after repeat extraction.

Conclusions: Coronectomy might reduce the risk of nerve injury for patients at true high risk of IANI as evaluated by dental computed tomography. A long-term postoperative review is needed to assess the incidence of root migration and the root extraction and infection rates after coronectomy.

© 2009 American Association of Oral and Maxillofacial Surgeons
J Oral Maxillofac Surg 67:1806-1814, 2009

Inferior alveolar nerve (IAN) injury (IANI) is a postoperative complication occurring after mandibular third molar extraction. The incidence of neurapraxia is about 1% to 5%,¹⁻³ and the rate of persistent IAN involvement has been reported at up to 0.9%.²⁻⁵ More than 30% of the IANIs have

been reported in confirmed cases of high-risk IAN involvement.⁶ Coronectomy (intentional partial odontectomy) is suggested as a method to minimize IANI for patients with high risks of nerve damage. However, only 5 reports have been previously published.⁷⁻¹¹

*Fellow, First Department of Oral and Maxillofacial Surgery, Aichi Gakuin University School of Dentistry, Nagoya, Japan.

†Professor and Chairman, First Department of Oral and Maxillofacial Surgery, Aichi Gakuin University School of Dentistry, Nagoya, Japan.

‡Assistant Professor, First Department of Oral and Maxillofacial Surgery, Aichi Gakuin University School of Dentistry, Nagoya, Japan.

§Director, Department of Oral and Maxillofacial Surgery, Tokai Sangyo Iryodan Chuo Hospital, Tokai, Japan.

¶Professor, Department of Oral and Maxillofacial Radiology, Aichi Gakuin University School of Dentistry, Nagoya, Japan.

Address correspondence and reprint requests to Dr Hatano: First Department of Oral and Maxillofacial Surgery, Aichi Gakuin University School of Dentistry, 2-11 Suemori-dori Chikusa-ku, Nagoya 464-8651 Japan; e-mail: goflb1111@mb.ccnw.ne.jp

© 2009 American Association of Oral and Maxillofacial Surgeons

0278-2391/09/6709-0004\$36.00/0

doi:10.1016/j.joms.2009.04.018

FIGURE 1. Trial profile.

Hatano et al. Coronectomy Using Dental CT. J Oral Maxillofac Surg 2009.

Although radiologic screening for patients at high risk of IANI is necessary for an indication for coronectomy, previous studies have assessed patients only using panoramic imaging. The panoramic radiograph features that predict IANI¹¹⁻¹⁷ do not indicate an accurate anatomic relation to the IAN because of the limitations of 2-dimensional imaging. No clinical trials of coronectomy have been reported using dental computed tomography (CT) to assess the true relationship to the IAN.

To more accurately evaluate the efficacy of coronectomy, we used dental CT for all patients at high risk of IANI. Our study was designed to assess the efficacy of coronectomy for IANI cases in which the roots were attached to the IAN.

Patients and Methods

The study was undertaken in our department from January 2006 to November 2007. [Figure 1](#) shows our study profile. Patients with high-risk signs of IANI on

panoramic imaging ([Fig 2](#)) were examined by dental CT. On dental CT, the patients with any close relationship between the third molar and the inferior alveolar canal were eligible for enrollment in the study ([Fig 3A](#)).

Patients who had no findings related to the inferior alveolar canal on dental CT were excluded ([Fig 3B](#)). We established criteria for the evaluation of the dental CT screening findings ([Fig 4](#)). We excluded patients who had cortical bone between the root and the IAN ([Fig 5](#)). Patients with contact of the IAN without cortical bone were enrolled in the present study.

Patients were excluded if they were younger than 16 years old (premature roots), had clinical signs of systemic infection, were medically compromised because of diabetes, chemotherapy, previous radiotherapy, immunologic disease, bone disease (ie, osteoporosis, osteosclerosis, or osteopetrosis), or had existing neural disorders or nonvital third molars.

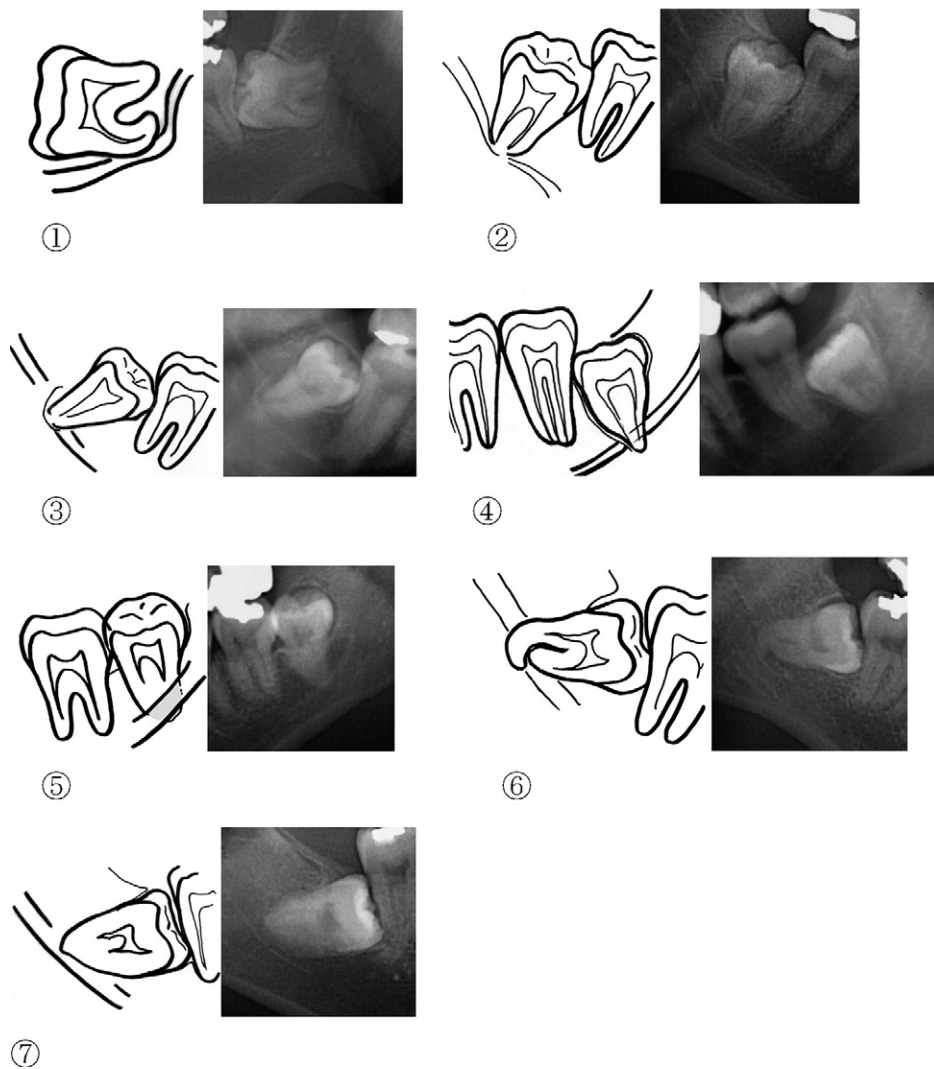


FIGURE 2. Radiographic signs of increased risk of inferior alveolar nerve injury: 1, deviation of the canal; 2, narrowing of the canal; 3, periapical radiolucent area; 4, narrowing of root; 5, darkening of roots; 6, curving of root; and 7, loss of lamina dura of canal.

Hatano et al. Coronectomy Using Dental CT. J Oral Maxillofac Surg 2009.

We informed patients about the traditional extraction and coronectomy procedures. After giving informed consent, the patients were assigned to 2 groups depending on their decision to undergo traditional extraction (control group; $n = 118$) or coronectomy (case group; $n = 102$). All patients were Asian, in whom the percentages of horizontal and vertical cases differ from those in whites. Thus, the surgical techniques and postoperative courses cannot be similarly compared.

The operations were performed by 1 of 6 board-certified oral and maxillofacial surgeons with the patient under local anesthesia. In the coronectomy group, a mucoperiosteal flap was raised, and the crown was resected below the cement-enamel junction. The resected surface was placed 3 to 4 mm from the alveolar bone crest. The wound was de-

brided, irrigated using saline, and closed primarily (Fig 6).

The surgeons examined the patients postoperatively. When patients showed signs of postoperative complications such as nerve injury or infection, they were followed until the symptoms had resolved. Patients who reported any neural symptoms were examined using the Semmes-Weinstein test. Patients who had undergone coronectomy returned to our hospital at 1, 3, 6, 9, and 12 months and then every year postoperatively. The remaining roots were examined with panoramic radiography at every visit and by dental CT at the 3- and 12-month visits and then annually.

The assessment for reoperation was done using physical examination and dental CT imaging at 3 months postoperatively. The remaining roots were removed

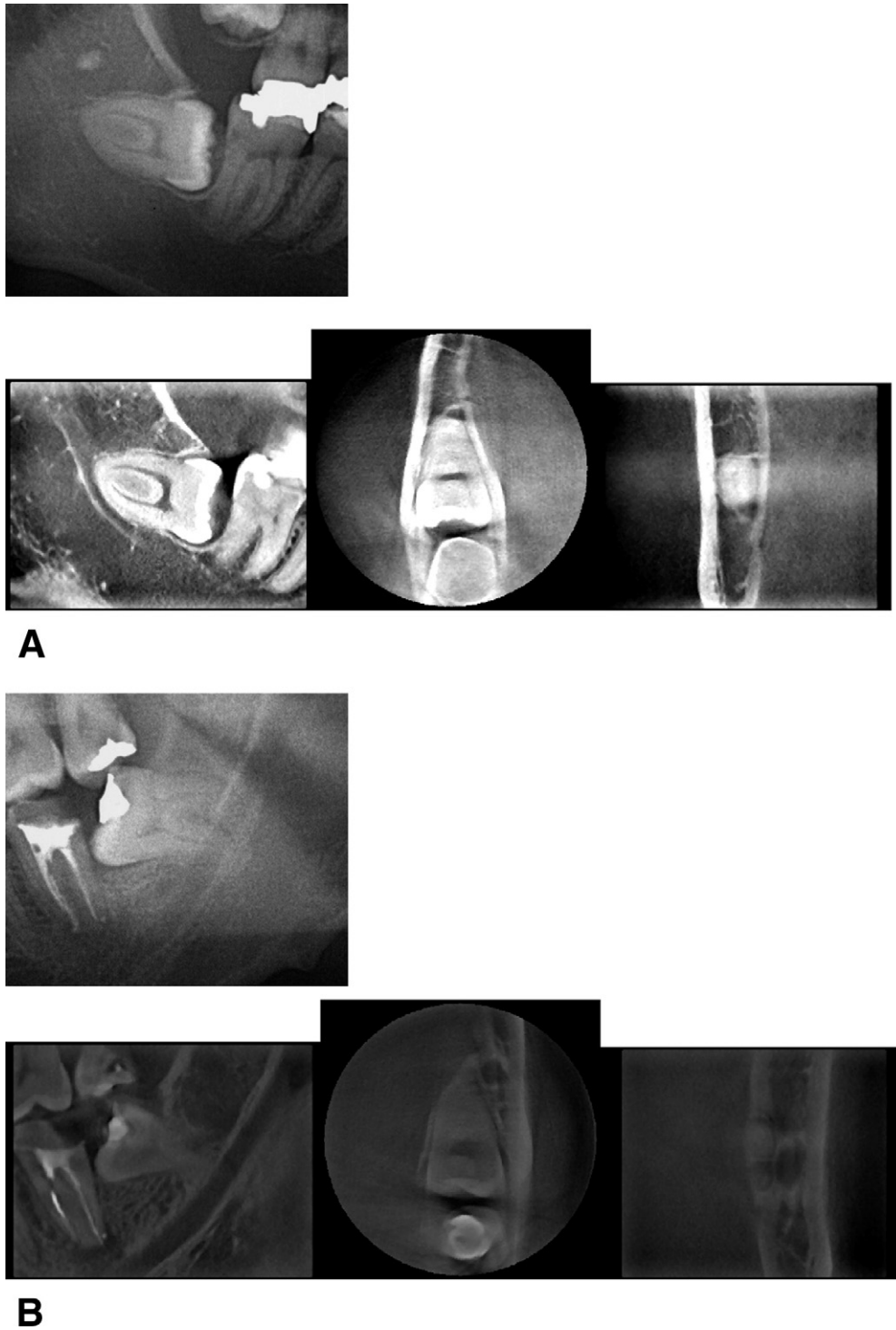


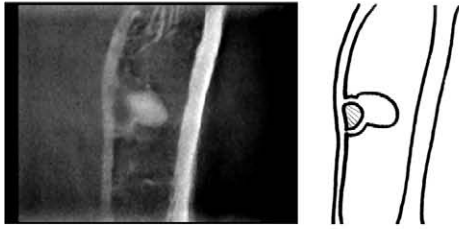
FIGURE 3. A, Inferior alveolar canal runs lingual at bottom of root, with no cortical bone present between root and nerve. B, Panoramic imaging indicates risk of IANI; however, no close relationships seen on CT.

Hatano et al. Coronectomy Using Dental CT. J Oral Maxillofac Surg 2009.

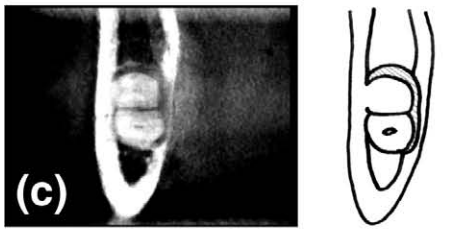
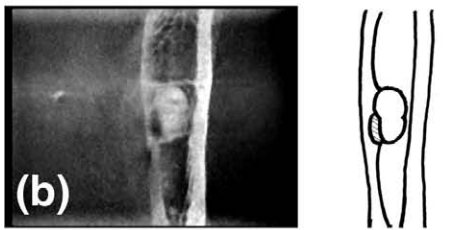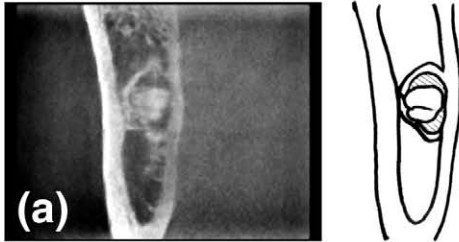
when they fulfilled all the following criteria for extraction: 1) root exposure to the oral cavity; 2) infectious signs (pus discharge, swelling, lymphadenopathy); and 3) root migration on dental CT image (Figs 7A,B).

Fisher's exact test was used to analyze the association between the operative methods and the outcome variables using the Statistical Package for Social Sciences, version 15J (SPSS, Tokyo, Japan).

Inclusion criteria:

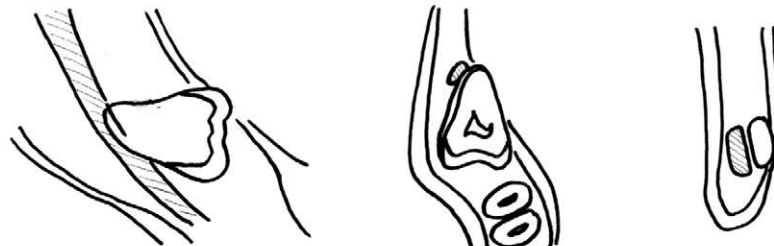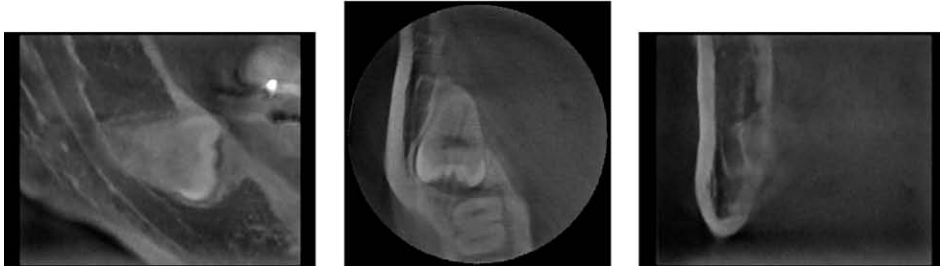


A. Point contacting the inferior alveolar nerve without the interstitial cortical bone



B. Directly contacting the inferior alveolar nerve with more than one surface

Exclusion criteria:



C. The interstitial cortical bone lying between the inferior alveolar nerve and the root

FIGURE 4. Criteria for dental CT evaluation. Criteria for inclusion: A, point contacting the inferior alveolar nerve without the interstitial cortical bone; and B, direct contact to IAN with more than 1 surface (a-c). Exclusion criteria: C, interstitial cortical bone lying between IAN and root.

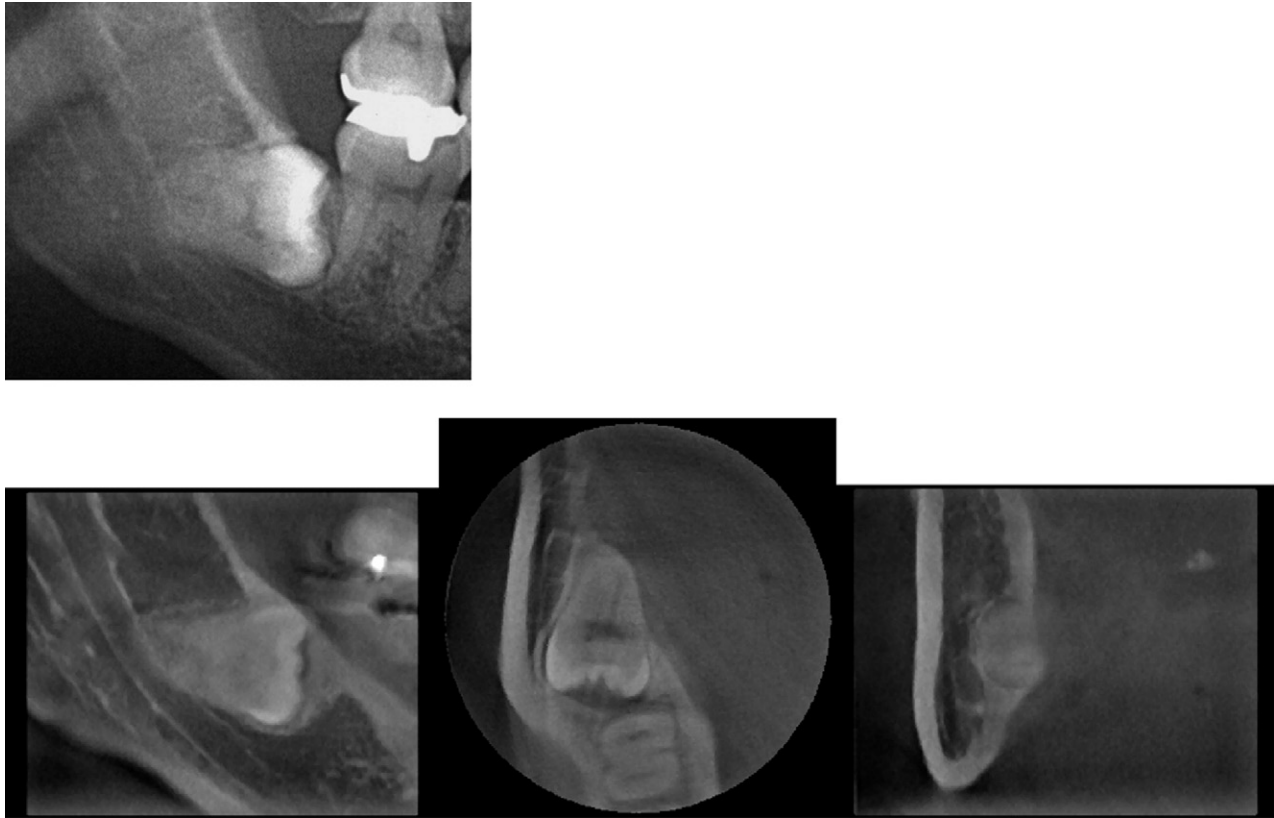


FIGURE 5. Even if IANs were very close to the root, cases with cortical bone layer were excluded.

Hatano et al. Coronectomy Using Dental CT. J Oral Maxillofac Surg 2009.

Results

Table 1 lists the characteristics of the patients and controls at study enrollment. The radiographic findings were similar between the 2 groups. No significant differences were found in age or gender. The median follow-up time was 13 ± 1.31 months in the extraction group and 13.5 ± 14.85 months in the coronectomy group.

Postoperative pain, measured using a visual analog scale, the maximal mouth opening range, and tenderness around the wound site are listed in

Table 2. In the extraction group, 6 patients (5%) showed signs of IANI. Of these 6 patients, 3 were diagnosed with permanent nerve injury. In the coronectomy group, 1 patient (1%) complained of nerve symptoms postoperatively but became asymptomatic within 1 month. No lingual nerve injuries were found in either group. Four patients (4%) in the coronectomy group had signs of infection postoperatively. We removed the remaining roots in these 4 cases. No nerve damage was found after re-extraction (Table 3).

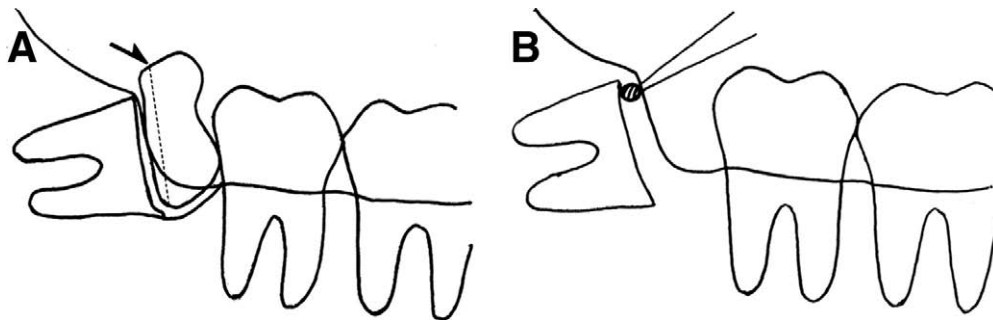


FIGURE 6. A, Cutting crown below cement-enamel junction (arrow). B, Trimming cutting surface to less than 3 to 4 mm below alveolar crest.

Hatano et al. Coronectomy Using Dental CT. J Oral Maxillofac Surg 2009.

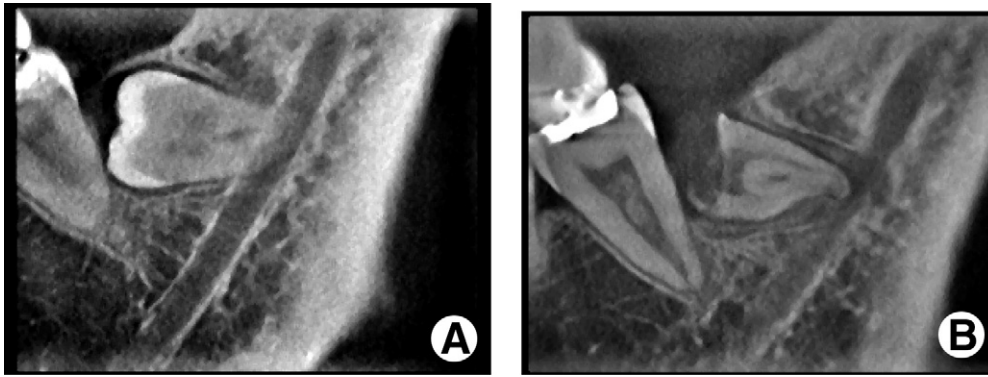


FIGURE 7. A, Preoperative dental CT image. B, Dental CT image at 3 months postoperatively.

Hatano et al. Coronectomy Using Dental CT. *J Oral Maxillofac Surg* 2009.

Discussion

Our results have provided evidence that coronectomy decreases the risk of IANI compared with traditional extraction of the mandibular third molar. No

significant difference was found in the characteristics or outcomes between our 2 groups.

Our results are consistent with those from a recent randomized clinical trial by Renton et al¹¹ and a retrospective study by O'Riordan.⁸ However, these studies used 2-dimensional radiograph imaging at enrollment.

The true relationship between the IAN and the roots cannot be obtained using 2-dimensional radiographs. Thus, we used dental CT for our secondary screening and the assessment during postoperative follow-up. Dental CT played a role in establishing our new criteria and ensuring safety for the removal of the remaining roots.

Table 1. PATIENT CHARACTERISTICS

Characteristic	Extraction Group (n = 118)	Coronectomy Group (n = 102)
Mean age (yr)	32.19 ± 8.47	32.36 ± 10.39
Gender		
Male	28.81 (34)	26.47 (27)
Female	71.19 (84)	73.53 (75)
Radiographic risk		
Darkening of roots	30.50 (36)	25.49 (26)
Deviation of canal	14.41 (17)	19.61 (20)
Loss of lamina dura	94.92 (112)	94.12 (96)
Narrowing canal	5.93 (7)	5.88 (6)
Juxta-apical area	6.78 (8)	5.88 (6)
Deflection roots	6.78 (8)	6.86 (7)
Narrowing roots	0 (0)	0.98 (1)
Angulation		
Vertical	22.03 (26)	4.90 (5)
Mesioangular	9.32 (11)	9.80 (10)
Distoangular	3.39 (4)	0.98 (1)
Horizontal	65.25 (77)	84.31 (86)
Root morphology		
Conical	5.93 (7)	12.75 (13)
Divergent	2.54 (3)	2.94 (3)
Club	5.08 (6)	10.78 (11)
Vertical relationship between root and IAC		
Root apex at upper half of IAC	89.83 (106)	82.35 (84)
Root apex at lower half of IAC	10.17 (12)	17.65 (18)

Data presented as mean ± standard deviation or percentages, with numbers in parentheses.

Abbreviation: IAC, inferior alveolar canal.

Table 2. IMMEDIATE POSTOPERATIVE FINDINGS

Variable	Extraction Group (n = 118)	Coronectomy Group (n = 102)
VAS		
Day of surgery	59.6	47.7
Postoperatively		
Day 1	37	32.6
Day 3	29.8	18.7
Day 5	20.2	17.8
Day 7	7.6	2.8
Postoperative MMO (mm)		
Day 1	35.6	35.1
Day 7	40	41.2
Postoperative tenderness (%)		
Day 1		
Yes	71.4	71.1
No	28.6	28.9
Day 7		
Yes	26.5	33.3
No	73.5	66.7

Abbreviations: VAS, visual analog scale; MMO, maximal mouth opening.

Hatano et al. Coronectomy Using Dental CT. *J Oral Maxillofac Surg* 2009.

Hatano et al. Coronectomy Using Dental CT. *J Oral Maxillofac Surg* 2009.

Table 3. FOLLOW-UP AND POSTOPERATIVE EVENTS

Variable	Extraction Group (n = 118)	Coronectomy Group (n = 102)	P Value
Review period (mo)	13 ± 1.31	13.5 ± 14.85	—
IANI	5.08 (6)	0.98 (1)	0.126
IANI duration (wk)	13.44 ± 86.27	7.14 ± —	—
Dry socket	8.47 (10)	1.96 (2)	0.039
Infection	3.39 (4)	0.98 (1)	0.376
Pain	6.78 (8)	18.63 (19)	0.012
Reoperation	—	4.90 (5)	—
Root migration	—	85.29 (87)	—
Failed coronectomy	5.06 (5)	—	—

Data presented as mean ± standard deviation or percentages, with numbers in parentheses.

Abbreviations: IAN, inferior alveolar nerve; IANI, IAN injury.

Hatano et al. Coronectomy Using Dental CT. J Oral Maxillofac Surg 2009.

One patient in the coronectomy group had symptoms of dysesthesia, which had ameliorated 3 weeks after the coronectomy. The patient’s preoperative radiograph showed darkening of the roots and the juxta-apical area (Fig 8A). The angulation of the tooth was vertical. On dental CT, the inferior alveolar canal was seen on the buccal side of the root and was in contact with 3 surfaces (Fig 8B). The cause of the neurapraxia might have been the stimulus that oc-

curred when the crown was removed. Mechanical stress during the crown transaction would have been transmitted around the root to the nerve sheath. Except for this transient symptom, this patient’s postoperative course was uneventful.

The incidence of postoperative pain was greater in the coronectomy group; however, all pain had decreased within 1 week. One cause might have been the tight primary closure, which could have caused a high pressure inside the wound and thus acute pain. Another reason might have been the temporary pulpitis of the resected roots. Dry sockets occurred more often in the extraction group, a finding that can be explained by the type of impaction. Many patients in our study had deeply impacted teeth; thus, a greater bone surface area was exposed inside the wound postoperatively. Insufficiently preventing blood clotting could also have occurred frequently. Detachment of blood clots did not occur often in the coronectomy group with the tight primary closure. The morbidity for dry sockets was accordingly greater in the extraction group.

Compared with vertically impacted teeth, treatment at the distal area after crown resection can often be complicated in horizontal cases. The distal alveolar crest tends to be thin and easily chipped during trimming of the resected surface. Such surgical difficulties depend on the tooth angulation, the depth of impaction, and the standing point of the ramus. Even if appropriate trimming 2 to 3 mm below the alveolar

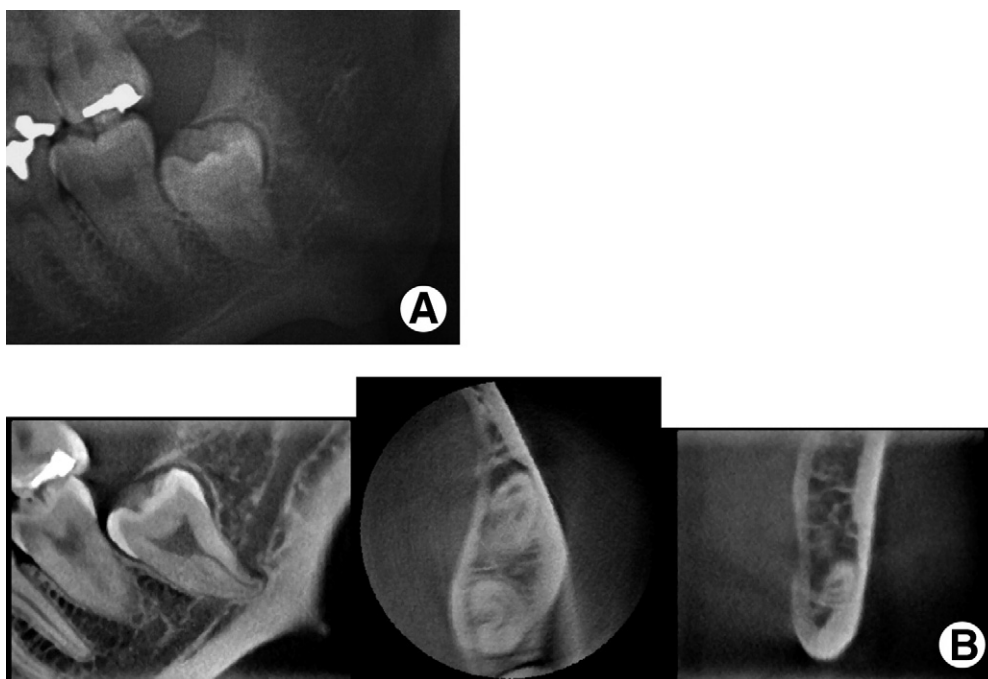


FIGURE 8. A, Preoperative panoramic radiograph. B, Preoperative dental CT scan.

Hatano et al. Coronectomy Using Dental CT. J Oral Maxillofac Surg 2009.

crest is done, bone coverage on the resected surface is sometimes delayed because of significant root migration.

Our study showed evidence that coronectomy can minimize nerve injury for patients at true risk of IANI. However, compared with the randomized controlled trial, the evidence level of a case-control study is lower and such studies contain a bias. For the greater evidence level, a randomized controlled trial would be better. Also, a study with a longer review period with a sufficient number of cases is needed to confirm our results. The issues remaining to be addressed include assessing root migration, which was found in most cases after coronectomy; defining the surgical guidelines; and research into the relationship between panoramic radiograph imaging and dental CT.

References

1. Carmichael FA, McGowan DA: Incidence of nerve damage following third molar removal: A West of Scotland Oral Surgery Research Group study. *Br J Oral Maxillofac Surg* 30:78, 1992
2. Schultze-Mosgau S, Reich RH: Assessment of inferior alveolar and lingual nerve disturbances after dentoalveolar surgery, and of recovery of sensitivity. *Int J Oral Maxillofac Surg* 22:214, 1993
3. Gülicher D, Gerlach KL: Sensory impairment of the lingual and inferior alveolar nerves following removal of impacted mandibular third molars. *Int J Oral Maxillofac Surg* 30:306, 2001
4. Valmaseda-Castellón E, Berini-Aytés L, Gay-Escoda C: Inferior alveolar nerve damage after lower third molar surgical extraction: A prospective study of 1117 surgical extractions. *Oral Surg Oral Med Oral Pathol Oral Radiol Endod* 92:377, 2001
5. Queral-Godoy E, Valmaseda-Castellón E, Berini-Aytés L, et al: Incidence and evolution of inferior alveolar nerve lesions following lower third molar extraction. *Oral Surg Oral Med Oral Pathol Oral Radiol Endod* 99:259, 2005
6. Howe GL, Poyton HG: Prevention of damage to the inferior dental nerve during the extraction of mandibular third molars. *Br Dent J* 109:355, 1960
7. Pogrel MA, Lee JS, Muff DF: Coronectomy: A technique to protect the inferior alveolar nerve. *J Oral Maxillofac Surg* 62:1447, 2004
8. O'Riordan BC: Coronectomy (intentional partial odontectomy of lower third molars). *Oral Surg Oral Med Oral Pathol Oral Radiol Endod* 98:274, 2004
9. Freedman GL: Intentional partial odontectomy: Review of cases. *J Oral Maxillofac Surg* 55:524, 1997
10. Knutsson K, Lysell L, Rohlin M: Postoperative status after partial removal of the mandibular third molar. *Swed Dent J* 13:15, 1989
11. Renton T, Hankins M, Sproate C, et al: Randomised controlled clinical trial to compare the incidence of injury to the inferior alveolar nerve as a result of coronectomy and removal of mandibular third molars. *Br J Oral Maxillofac Surg* 43:7, 2005
12. Rood JP, Shehab BA: The radiological prediction of inferior alveolar nerve injury during third molar surgery. *Br J Oral Maxillofac Surg* 28:20, 1990
13. Blaeser BF, August MA, Donoff RB, et al: Panoramic radiographic risk factors for inferior alveolar nerve injury after third molar extraction. *J Oral Maxillofac Surg* 61:417, 2003
14. Sedaghatfar M, August MA, Dodson TB: Panoramic radiographic findings as predictors of inferior alveolar nerve exposure following third molar extraction. *J Oral Maxillofac Surg* 63:3, 2005
15. Bell GW, Rodgers JM, Grime RJ, et al: The accuracy of dental panoramic tomographs in determining the root morphology of mandibular third molar teeth before surgery. *Oral Surg Oral Med Oral Pathol Oral Radiol Endod* 95:119, 2003
16. Smith AC, Barry SE, Chiong AY, et al: Inferior alveolar nerve damage following removal of mandibular third molar teeth: A prospective study using panoramic radiography. *Aust Dent J* 42:149, 1997
17. Monaco G, Montevecchi M, Bonetti GA, et al: Reliability of panoramic radiography in evaluating the topographic relationship between the mandibular canal and impacted third molars. *J Am Dent Assoc* 135:312, 2004