

Treatment of Keratocysts: The Case for Decompression and Marsupialization

M. Anthony Pogrel, DDS, MD*

Decompression of a cyst involves any technique that relieves the pressure within the cyst that causes it to grow. Growth of cysts is believed to occur by a combination of osmotic pressure and pressure resorption,¹ coupled with release of prostaglandins and growth factors.² Decompression, by any means, appears to change to environment and decreases the amount of interleukin- α that is released.³ Decompression can be performed by making a small opening in the cyst and keeping it open with a drain of some kind⁴⁻⁷ (Fig 1). Marsupialization, on the other hand, involves converting the cyst into a pouch. (The word *marsupial* is derived from the Greek for "pouch") (Fig 2). By converting the cyst to a pouch, the lesion is decompressed, but this is a more definitive treatment for the cavity and exposes the cyst lining to the oral environment.⁸ Mandibular cysts are normally marsupialized into the oral cavity, although maxillary cysts can also be marsupialized into the maxillary sinus or nasal cavity, as well as the oral cavity⁹ (Fig 3).

Decompression and marsupialization of cysts is probably the earliest advocated treatment and was first suggested by Partsch in the German literature in the late 19th century.^{10,11} In many parts of the world, marsupialization is still described as a Partsch I procedure (the Partsch II procedure is enucleation and primary closure). At the time, this method was put forward as the treatment of choice, because without antibiotics any attempt at enucleation and primary closure of a cyst was accompanied by a very high postoperative infection rate.¹²

Decompression, marsupialization, or open packing of the lesion appeared to have a much better prognosis.

With the advent of antibiotics and the routine use of endotracheal intubation, however, the management of dental cysts changed. Enucleation and primary closure became the more accepted treatment, and to many, decompression and marsupialization were resigned to the history books. Although it was always thought by some that odontogenic keratocysts could be marsupialized, this has not been the treatment of choice, and in fact in many hands treatment of the odontogenic keratocyst has become more aggressive over the years in order to combat the known recurrence rate.¹³⁻¹⁸ However, articles have been published on decompression and marsupialization showing that it does still work for these lesions despite their supposedly more aggressive nature, and on looking again at this issue, it does appear that this treatment may have an expanded role.

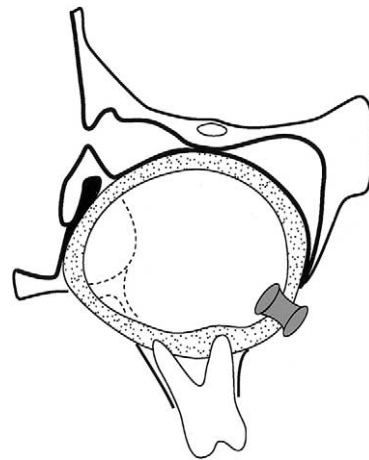


FIGURE 1. Diagrammatic representation of decompression of a large maxillary cyst into the oral cavity with a drainage tube in place.

M. Anthony Pogrel. *Decompression and Marsupialization of Keratocysts.* J Oral Maxillofac Surg 2005.

*Professor and Chairman, Department of Oral and Maxillofacial Surgery, University of California-San Francisco, San Francisco, CA.

Address correspondence and reprint requests to Dr Pogrel: Department of Oral and Maxillofacial Surgery, University of California-San Francisco, 521 Parnassus Ave, C-522, Box 0440, San Francisco, CA 94143-0440; e-mail: map@itsa.ucsf.edu

© 2005 American Association of Oral and Maxillofacial Surgeons

0278-2391/05/6311-0016\$30.00/0

doi:10.1016/j.joms.2005.08.008

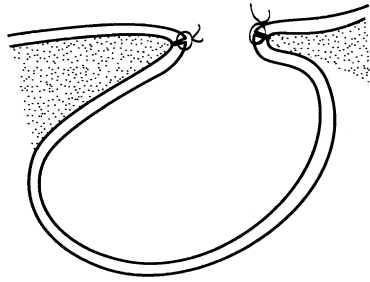


FIGURE 2. Diagrammatic representation of marsupialization with the cyst mucosa sutured to the oral cavity mucosa.

M. Anthony Pogrel. Decompression and Marsupialization of Keratocysts. J Oral Maxillofac Surg 2005.

Several studies have shown that decompression by making a small opening into the cyst and inserting a grommet, or drainage tube, can result in substantial reduction in the size of the cyst.^{5,6,19,20} This is recommended to decrease the size of the cyst to take it away from important structures such as teeth and the inferior alveolar nerve and to

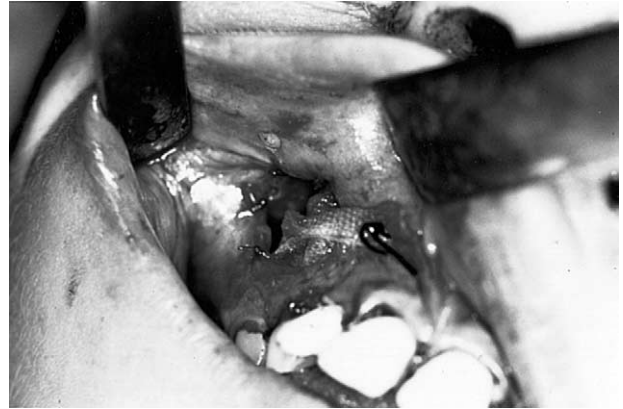

FIGURE 4. A large maxillary keratocyst packed with iodoform gauze and bacitracin.

M. Anthony Pogrel. Decompression and Marsupialization of Keratocysts. J Oral Maxillofac Surg 2005.

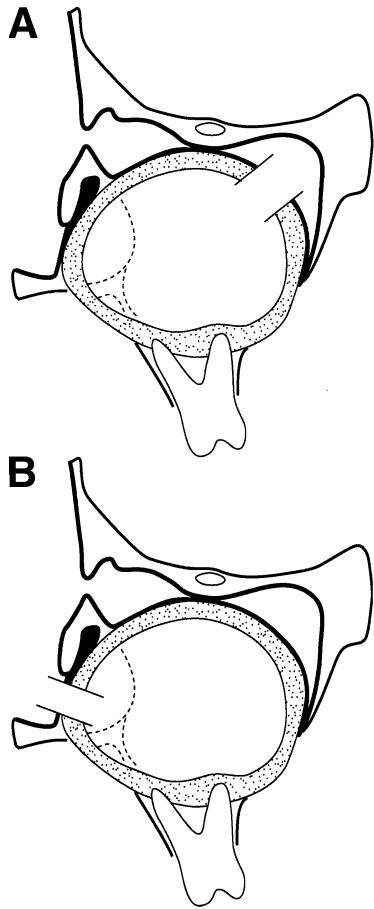


FIGURE 3. A, The concept of marsupialization of a maxillary cyst into the sinus. B, Marsupialization of maxillary cyst into the nasal cavity.

M. Anthony Pogrel. Decompression and Marsupialization of Keratocysts. J Oral Maxillofac Surg 2005.

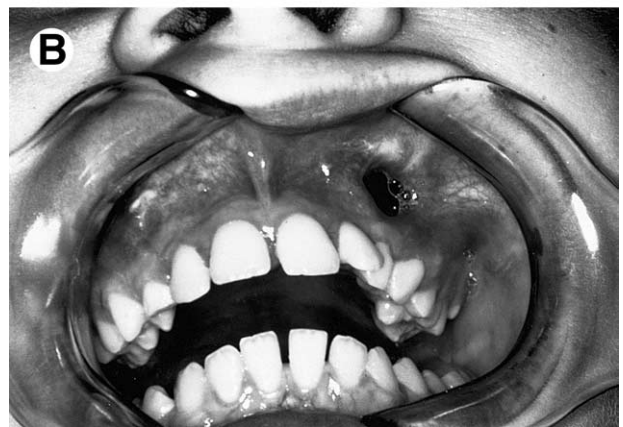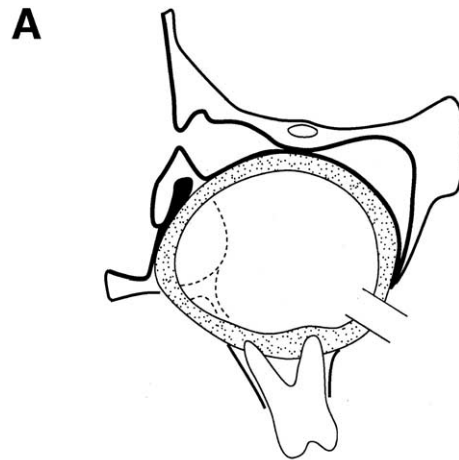


FIGURE 5. Maxillary keratocyst remains open to the oral cavity after removal of the packing. A, Diagram. B, Clinical Photograph.

M. Anthony Pogrel. Decompression and Marsupialization of Keratocysts. J Oral Maxillofac Surg 2005.

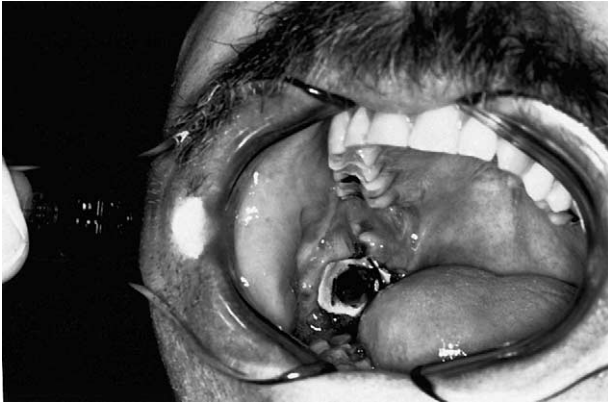

FIGURE 6. A mandibular keratocyst kept patent by suturing a cut-down nasopharyngeal airway into place.

M. Anthony Pogrel. Decompression and Marsupialization of Keratocysts. J Oral Maxillofac Surg 2005.

reduce the chance of a pathologic fracture or bony discontinuity with definitive treatment. With this decompression technique, subsequent enucleation of the smaller lesion is then usually performed.

Other studies have shown that a more formal technique for marsupialization of these lesions can be followed by total resolution of the lesion without any further surgery.^{4,21-23} In this technique, a window at least 1 cm in diameter is made into the cyst, and an attempt is made to suture the cyst lining to the oral mucosa. In the maxilla, the cyst is often then packed open with the packing protruding through the opening. The packing consists of iodoform gauze impregnated with bacitracin ointment (Fig 4). When it is removed in the maxilla, the cavity is usually self-retaining and the patient needs to irrigate twice a day to prevent food accumulation or closure of the fistula (Fig 5). In the mandible, there is a greater tendency for spontaneous closure of the fistula and reformation of the cyst, particularly in the posterior mandible. In these cases, we have found that the use of a nasopharyngeal anesthesia tube suitably cut down makes an excellent stent to keep the cyst open (Fig 6). Again, the cavity is irrigated twice daily.

Studies have shown that when the keratocyst is open to the oral cavity, a number of changes take

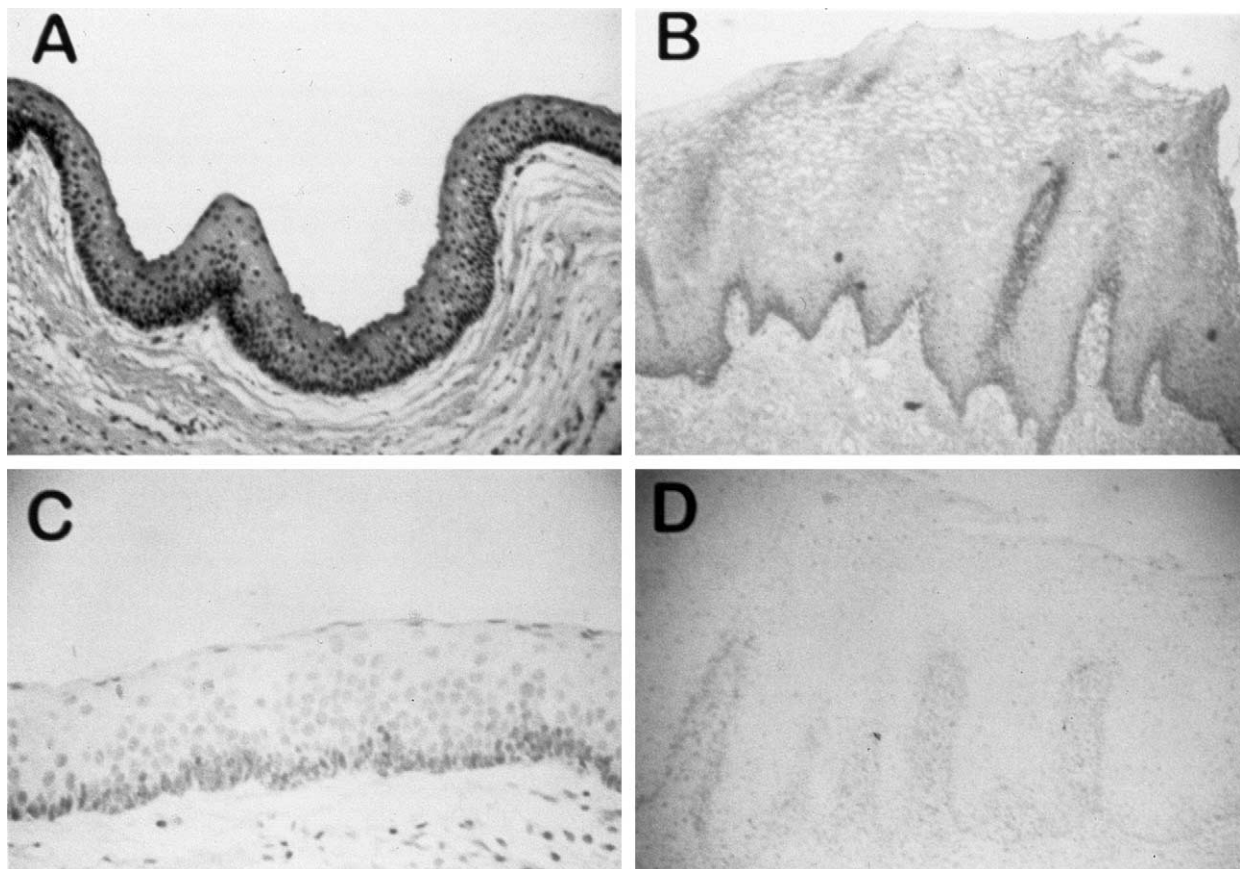


FIGURE 7. A, Biopsy of keratocyst lining (hematoxylin and eosin, original magnification times 40). B, Positive bcl-2 staining in the basal layer of the biopsy. C, Residual lining after marsupialization (hematoxylin and eosin, original magnification times 40). D, Residual lining after marsupialization shows no bcl-2 staining and shows the histology and immunostaining of normal oral mucosa.

M. Anthony Pogrel. Decompression and Marsupialization of Keratocysts. J Oral Maxillofac Surg 2005.

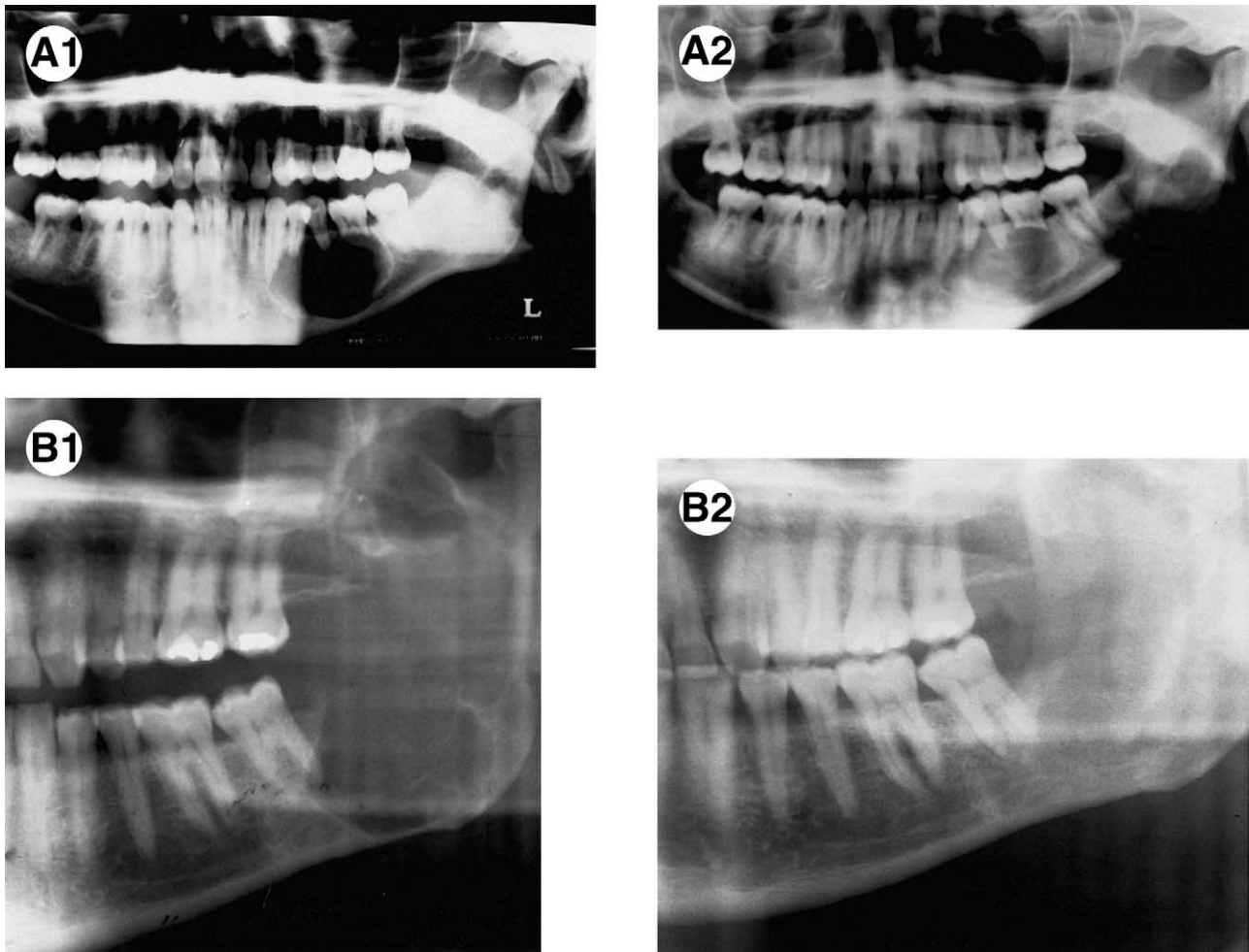


FIGURE 8. Radiographs for two cases of large keratocysts of the mandible which resolved following marsupialization. A, A large cyst of the left angle before (A1) and 11 months after (A2) marsupialization. B, A unilocular keratocyst of the left mandibular angle at initial presentation (B1) and 1 month following marsupialization showing the resolution (B2).

M. Anthony Pogrel. Decompression and Marsupialization of Keratocysts. J Oral Maxillofac Surg 2005.

place in the cyst lining. Traditionally, the lining of a keratocyst is only 5 or 6 cells thick and tears easily on attempted enucleation; this may at least partially account for the traditionally high recurrence rate. With decompression or marsupialization, the lining appears to become thicker and easier to enucleate, and histologically it does appear to change and resemble normal oral mucosa^{23,24} (Fig 7), both with routine histology and with immunohistochemistry including bcl-2²³ and cytokeratin 10 immunostaining.²⁴ Whether this means that there is metaplasia of the keratocyst lining to oral mucosa or overgrowth of the oral mucosa is unknown at the present time.²

Studies have shown that this marsupialization technique can result in total elimination of even large keratocysts in less than 1 year²³ (Figs 8, 9). By comparison with larger dentigerous cysts treated by marsupialization, it actually appears that the

technique is at least as successful for keratocysts and may be even more successful than for the dentigerous cyst.

Although it is freely admitted that other techniques may be at least as successful in permanently curing the patient of the odontogenic keratocyst, decompression or marsupialization has distinct advantages in preserving vital structures and eliminating major surgical procedures. The important points in favor of this technique are as follows:

Decompression

1. If decompression is performed, the cyst will decrease in size and there will be less damage to important structures on subsequent enucleation.
2. Subsequent enucleation will be easier as the cyst lining will be thicker.

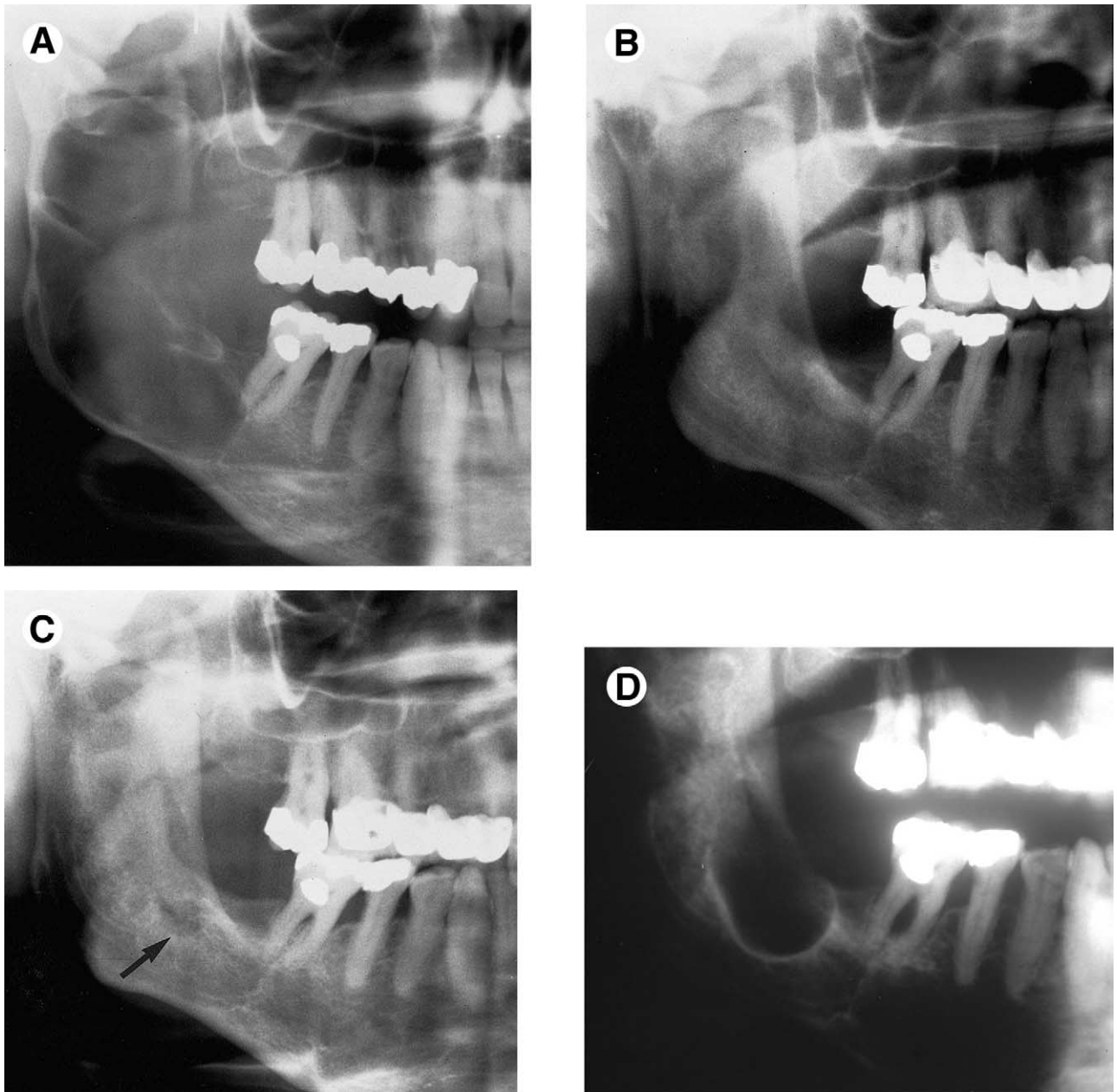


FIGURE 9. Recurrence of a keratocyst following marsupialization. A, Original radiograph showing large multilocular keratocyst of right angle of the mandible. B, Resolution after 1 year of marsupialization. C, Recurrence just visible 1 year later (arrowed). D, Recurrence after 18 months when it was surgically resected.

M. Anthony Pogrel. Decompression and Marsupialization of Keratocysts. J Oral Maxillofac Surg 2005.

If Marsupialization is Used for Complete Resolution

1. The patient must be cooperative and irrigate the cyst at least twice a day.
2. A stent may need to be placed in the cyst to maintain the opening.
3. Studies show that complete elimination of the cyst is possible with marsupialization.
4. The cyst lining changes to resemble normal oral mucosa.
5. In the authors' hands, they have only seen one recurrence of a total of 20 cysts treated this way, for a 5% recurrence rate. This case is shown in [Figure 9](#).

In conclusion, decompression and/or marsupialization has at least as high a success rate as more

aggressive treatments with lower morbidity and preservation of important dental and neural structures.

Liquid Nitrogen Cryotherapy

For some patients, decompression or marsupialization is impractical or difficult to perform. Patients in this category would include those who are unable to cooperate with the oral hygiene regimen that is necessary, patients for whom the time frame is inappropriate (marsupialization can take a year or longer to perform), or for reasons of patient preference. In this case, the treatment of choice becomes enucleation followed by cryotherapy using a liquid nitrogen spray.²⁵ It has been shown that enucleation alone for the management of these lesions is associated with an unacceptable recurrence rate of between 5% and 65%.^{26,27} However, with cryotherapy the recurrence rate is reduced considerably. The cryotherapy devitalizes organic tissue beyond the visible margin of the lesion but leaves the inorganic bony framework intact. In this way, any adjacent daughter cells or cyst remnants will be destroyed. It has been shown that liquid nitrogen cryospray devitalizes an area between 1 and 2 mm beyond the visible margins of the lesion, which should be adequate for most lesions.²⁸ A temperature of -20°C is required to devitalize tissues, and only liquid nitrogen can deliver this on a consistent basis. A triple freeze/thaw technique is recommended with a 1-minute freeze followed by a slow thaw for each cycle.²⁹ Care must be taken to protect the soft tissues (9% soft tissue breakdown¹⁶) and protect the mandible from late pathologic fracture (9% fracture rate¹⁶).

The advantages of liquid nitrogen over alternative methods of devitalizing tissue beyond the visible lesion of the margin are that 1) the bone matrix is left in place to act as a clean scaffold for new bone formation and 2) a bone graft can be placed immediately to accelerate healing and minimize the risk of a pathologic fracture.³⁰

The recurrence rate following enucleation and liquid nitrogen cryotherapy has been reported at 9% (3 of 33), but in fact some of these recurrences were due to operator error or unsound patient preferences, including deliberately leaving teeth in the area being sprayed. If these cases are discounted, the recurrence rate following liquid nitrogen cryotherapy drops to around 3% (1 of 33).³¹ When the liquid nitrogen cryotherapy is given around the inferior alveolar nerve, it is affected, and patients will suffer paresthesia or anesthesia. However, the axon sheaths are left intact and nerve

regrowth is normal such that most patients obtain partial or complete return of sensation in 3 months.^{31,32}

References

1. Toller PA: The osmolality of fluids from cysts of the jaws. *Br Dent J* 129:275, 1970
2. Harris M: Odontogenic cyst growth and prostaglandin-induced bone resorption. *Ann R Coll Surg Engl* 60:85, 1978
3. Ninomiya T, Kubota Y, Koji T, et al: Marsupialization inhibits interleukin1alpha expression and epithelial cell proliferation in odontogenic keratocysts. *J Oral Pathol Med* 31:526, 2002
4. Eyre J, Zakrzewska JM: The conservative management of large odontogenic keratocysts. *Br J Oral Maxillofac Surg* 23:195, 1985
5. Brondum N, Jensen VJ: Recurrence of keratocysts and decompression treatment. A long-term follow-up of forty-four cases. *Oral Surg Oral Med Oral Pathol* 72:265, 1991
6. Marker P, Brondum N, Clausen PP, et al: Treatment of large odontogenic keratocysts by decompression and later cystectomy: A long-term follow-up and a histologic study of 23 cases. *Oral Surg Oral Med Oral Pathol Oral Radiol Endod* 82:122, 1996
7. Nakamura N, Mitsuyasu T, Mitsuyasu Y, et al: Marsupialization for odontogenic keratocysts: Long-term follow-up analysis of the effects and changes in growth characteristics. *Oral Surg Oral Med Oral Pathol Oral Radiol Endod* 94:543, 2002
8. Pogrel M: Decompression and marsupialization as a treatment for the odontogenic keratocyst. *Oral Maxillofac Surg Clin N Am* 15:415, 2003
9. Seward MH, Seward GR: Observations on Snawdon's technique for the treatment of cysts in the maxilla. *Br J Oral Surg* 6:149, 1969
10. Patsch C: Uber kiefercysten. *Deutsche Monatsschrift Fur Zahnheilkunde* 10:271, 1892
11. Patsch C: Zur behandlung der kieferzysten. *Deutsche Monatsschrift Fur Zahnheilkunde* 28:252, 1910
12. Dowsett E: Operative procedure for cysts of the jaws. *Proc R Soc Med* 25:4756, 1932
13. Jensen J, Sindet-Pedersen S, Simonsen EK: A comparative study of treatment of keratocysts by enucleation or enucleation combined with cryotherapy. A preliminary report. *J Craniomaxillofac Surg* 16:362, 1988
14. Voorsmit RA, Stoeltinga PJ, van Haelst UJ: The management of keratocysts. *Maxillofac Surg* 9:228, 1981
15. Irvine GH, Bowerman JE: Mandibular keratocysts: Surgical management. *Br J Oral Maxillofac Surg* 23:204, 1985
16. Schmidt BL, Pogrel MA: The use of enucleation and liquid nitrogen cryotherapy in the management of odontogenic keratocysts. *J Oral Maxillofac Surg* 59:720; discussion 726, 2001
17. Stoeltinga PJ: Long-term follow-up on keratocysts treated according to a defined protocol. *Int J Oral Maxillofac Surg* 30:14, 2001
18. Bramley P: The odontogenic keratocyst: An approach to treatment. *Int J Oral Surg* 3:337, 1974
19. Tucker WM, Pleasants JE, MacComb WS: Decompression and secondary enucleation of a mandibular cyst: Report of case. *J Oral Surg* 30:669, 1972
20. Rud J, Pindborg JJ: Odontogenic keratocysts: A follow-up study of 21 cases. *J Oral Surg* 27:323, 1969
21. Hopper FE: Bilateral cysts of the mandible. A unique opportunity? *Br Dent J* 153:306, 1982
22. Cranin AN, Madan S, Fayans E: Novel method of treating large cysts of jaws in children. *N Y State Dent J* 60:41, 1994
23. Pogrel MA: Marsupialization as a definitive treatment for the odontogenic keratocyst. *J Oral Maxillofac Surg* 62:651, 2004
24. August M, Faquin WC, Troulis M, et al: Differentiation of odontogenic keratocysts from nonkeratinizing cysts by use of fine-needle aspiration biopsy and cytokeratin-10 staining. *J Oral Maxillofac Surg* 58:935; discussion 940, 2000
25. Pogrel MA: The management of lesions of the jaws with liquid nitrogen cryotherapy. *J Calif Dent Assoc* 23:54, 1995

26. Vedtofte P, Praetorius F: Recurrence of the odontogenic keratocyst in relation to clinical and histological features. A 20-year follow-up study of 72 patients. *Int J Oral Surg* 8:412, 1979
27. Brannon RB: The odontogenic keratocyst. A clinicopathologic study of 312 cases. Part I. Clinical features. *Oral Surg Oral Med Oral Pathol* 42:54, 1976
28. Pogrel MA, Regezi JA, Fong B, et al: Effects of liquid nitrogen cryotherapy and bone grafting on artificial bone defects in minipigs: A preliminary study. *Int J Oral Maxillofac Surg* 31: 296, 2002
29. Pogrel MA: The use of liquid nitrogen cryotherapy in the management of locally aggressive bone lesions. *J Oral Maxillofac Surg* 51:269; discussion 274, 1993
30. Salmassy DA, Pogrel MA: Liquid nitrogen cryosurgery and immediate bone grafting in the management of aggressive primary jaw lesions. *J Oral Maxillofac Surg* 53:784, 1995
31. Schmidt BL: Neurosensory changes following cryotherapy. *J Oral Maxillofac Surg* 57:46, 1999 (suppl)
32. Schmidt BL: The use of liquid nitrogen cryotherapy in the management of the odontogenic keratocyst. *Oral Maxillofac Surg Clin N Am* 15:393, 2003