

Traumatic Changes of the Inferior Alveolar Nerve and Gasserian Ganglion After Removal of a Mandibular Third Molar: Report of a Case

Lars Eriksson, DDS, PhD,* Sören Hillerup, DDS, Dr Odont,†
Jesper Reibel, DDS, Dr Odont,‡ Sixten Persson, DDS, MD,§ and
Arne Brun, MD, PhD||

Dentoalveolar surgery, in particular the removal of mandibular third molars, may cause damage to the inferior alveolar nerve (IAN).¹ Once the magnitude of sensory dysfunction has been determined, expectancy versus surgical repair may be considered. However, the results of surgical intervention are difficult to assess from the few reports published.²⁻⁵ Some authors claim that early nerve repair appears to provide better results than does late nerve repair.^{6,7} According to Pogrel¹ this is not universally accepted and there are reports claiming that timing has little, if any, effect on the success of nerve repair procedures.^{5,8,9}

In clinical care, the option of comparing history and clinical status with histological changes of a major part of a traumatized mandibular nerve after removal of a third molar is virtually nonexistent. The case reported here has given us a unique opportunity for such a comparison.

*Professor, Department of Oral and Maxillofacial Surgery, Faculty of Odontology, University of Malmö, and University Hospital of Malmö, Malmö, Sweden.

†Associate Professor, Department of Oral and Maxillofacial Surgery, University Hospital of Copenhagen, Copenhagen, Denmark.

‡Professor and Head, Department of Oral Medicine and Oral Pathology, School of Dentistry, Faculty of Health Sciences, University of Copenhagen, Copenhagen, Denmark.

§Doctor, Department of Forensic Medicine, University of Lund, Lund, Sweden.

||Professor Emeritus, Faculty of Medicine, University of Lund and the Department of Pathology, University Hospital of Lund, Lund, Sweden.

Address correspondence and reprint requests to Dr Eriksson: Department of Oral and Maxillofacial Surgery, University Hospital of Malmö, SE 205 02 Malmö, Sweden; e-mail: lars.o.eriksson@skane.se

© 2006 American Association of Oral and Maxillofacial Surgeons

0278-2391/06/6412-0020\$32.00/0

doi:10.1016/j.joms.2005.11.040

Report of a Case

CLINICAL HISTORY

A 55-year-old woman was admitted for evaluation and treatment of severe pain in her lower left mandible. The patient complained of a concomitant feeling of slight swelling of her left cheek and a disturbed sensation of the left side of her lower lip. She had had a partially impacted mandibular left third molar surgically removed 6 months earlier at another hospital because of pericoronitis and deep pocket formation distally on the neighboring second molar (Fig 1).

During the first postoperative weeks, the patient had no sensory function in the left side of her lower lip but it gradually returned, unfortunately with associated neurogenic malfunction as pain and hyperesthesia. The patient also had noticed that "small hard pieces" had appeared at the extraction site postoperatively. On the tentative diagnosis of osteomyelitis, the patient had been treated with antibiotics. At the time of consultation, 6 months after removal of the lower third molar, she felt depressed and complained of increasing anxiety.

The surgical site was found to be healed, and the marginal periodontal status around the second molar was normal. The lower lip proved perceptive for featherlight touch by a brush and some ability to discriminate heat and cold, and also had 2-point discrimination ability. In all tests, however, outcome scores were lower than on the healthy side. Palpation of the mucosa in the third molar region triggered a severe pain that radiated to the left side of her lower lip.

Various attempts at pain control were undertaken. A mandibular nerve block with 5-mL bupivacaine HCl 2.5 mg/mL + epinephrine 5 µg/mL (Marcaïn; AstraZeneca, Sodertälje, Sweden) kept the patient free of pain for some hours but had no long-lasting effect. Prednisolon 30 mg (Prednisolon; Pharmacia & Upjohn, Kalamazoo, MI), per day for 3 days had no effect on the pain. The patient's mental status got worse and she was hospitalized for psychiatric treatment.

Because of the severe pain situation and observed radiographic changes of the mandibular canal that appeared to deflect cranially into the radiolucent area of the former alveolus, a neurolysis was performed in an effort to relieve tension and pressure to the IAN.

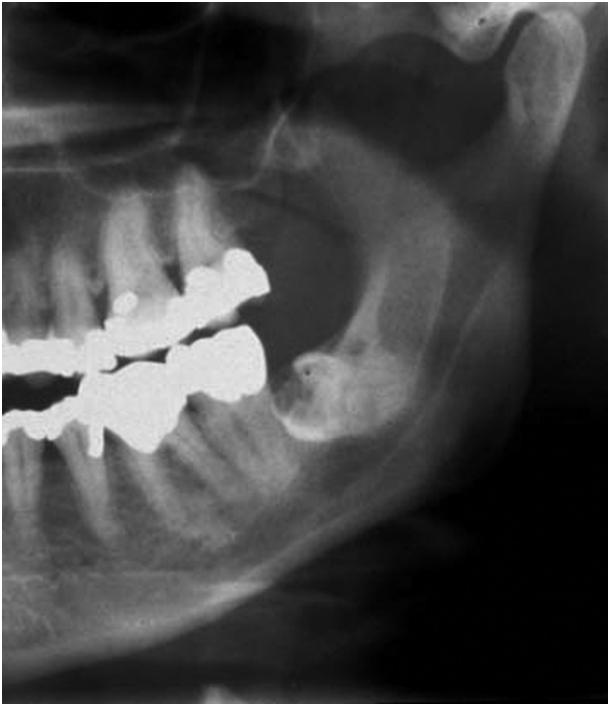

FIGURE 1. Part of panoramic radiograph with semiretained lower left third molar with resorption in the crown.

Eriksson et al. Traumatic Changes After Removal of Third Molar. J Oral Maxillofac Surg 2006.

After the neurolysis there was no pain and the patient felt mentally improved. The sensory function of the left IAN was markedly reduced. Two weeks later there was a creeping sensation in the left side of the lower lip, but still no pain. One month after the reoperation the patient occasionally felt pain on chewing. However, now the patient's main problem was periods of severe agony. Two months postoperatively the patient experienced that the teeth in the lower left jaw were pressed together and there was some pain in the lower lip. Four months after the neurolysis the pain situation was the same as preoperatively. The patient's mental status worsened severely and she had to be treated periodically as a psychiatric inpatient.

According to a neurosurgical consultation, the results of further surgical procedures were thought to be uncertain, for which reason the patient declined further surgery. Eighteen months after the removal of the third molar and 7 months after the neurolysis the patient committed suicide.

PATHOANATOMICAL FINDINGS

At autopsy the right and left ganglion Gasseri were extirpated and examined as a part of the routine autopsy procedure. On the right side it was possible to extirpate about 2 cm of the mandibular nerve for comparison with the left side. From an ethical point of view, more of the right nerve could not be extirpated to avoid a mutilating procedure. On the left side the mandibular nerve was extirpated from Gasserian ganglion to foramen mentale. About 2 cm of the proximal part of the lingual nerve was also included. A part of the mandible corresponding to the extension of the extirpated inferior alveolar nerve was removed. The bone and bone marrow appeared normal in the third molar area.

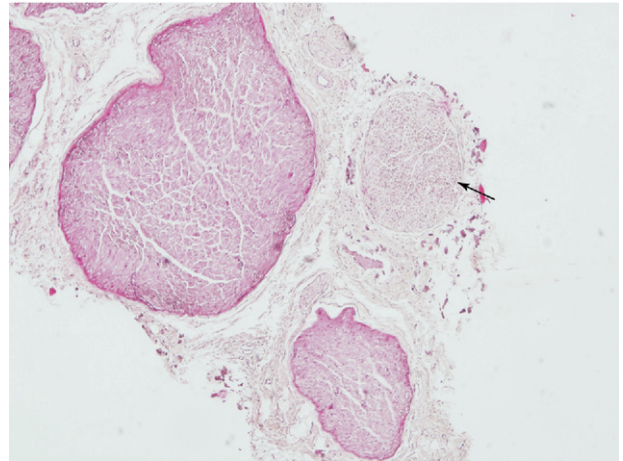


FIGURE 2. Transverse section of left inferior alveolar nerve showing two preserved fascicles with dense and stainable structure compared with one pale, degenerated fascicle (arrow) that is also hypercellular. (Hematoxylin-eosin stain; magnification $\times 4$.)

Eriksson et al. Traumatic Changes After Removal of Third Molar. J Oral Maxillofac Surg 2006.

In one small area centrally in the bone, bone resorption was evident and bone marrow and resorbed bone were replaced by fibrous tissue. Also, new bone formation was noted in this area. A few scattered lymphocytes were present, but there was no inflammation. A number of small peripheral nerves were seen in the fibrous tissue. The histology was considered to represent persisting bone remodeling in the previous alveolus of the third molar.

The removed left IAN was histologically disorganized, split up in nerve fascicles of various sizes embedded in and separated by collagenous connective tissue, which also infiltrated the fascicles and in some locations surrounded single myelin sheaths (Figs 2-5). A few intact nerve fascicles were also seen. The right nerve showed a normal structure and is included for comparison (Fig 6).

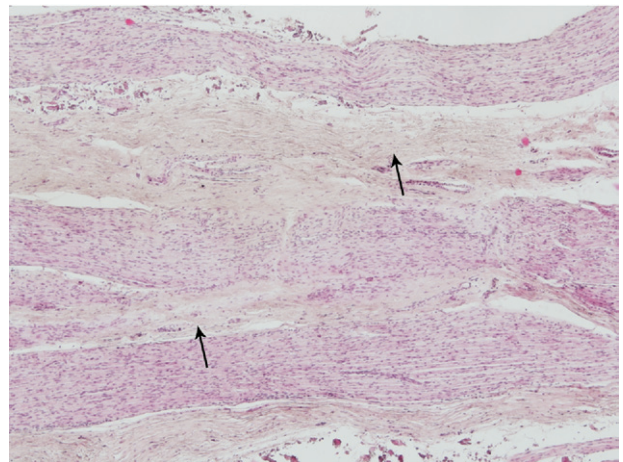


FIGURE 3. Left inferior alveolar nerve with degenerated pale, relatively acellular fascicles (arrows) alternating with dense preserved fascicles. (Hematoxylin-eosin stain; magnification $\times 4$.)

Eriksson et al. Traumatic Changes After Removal of Third Molar. J Oral Maxillofac Surg 2006.

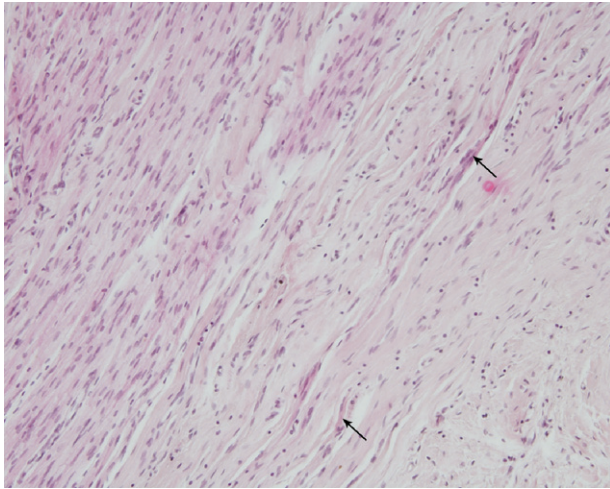


FIGURE 4. Most severely damaged part of the left inferior alveolar nerve, to the right with collagenous scar tissue and ingrowth of myelinated axons (arrows). (Hematoxylin-eosin stain; magnification $\times 10$.)

Eriksson et al. Traumatic Changes After Removal of Third Molar. J Oral Maxillofac Surg 2006.

Round cells were sparse in the scarred nerve tissue (Fig 7). Calcifications and foreign body granulomas were observed in some areas (Fig 8). Immunohistochemically single axons were found far out in the collagenous connective tissue. Distal to the third molar region, most nerve fascicles were intact except for some degenerated fascicles that were lacking axons (Wallerian degeneration).

The proximal part of the nerve that had been located in the mandibular ramus had intact nerve fascicles without scarring, but the density of the myelin sheaths was reduced. The extirpated part of the lingual nerve was intact.

At the proximal end of the mandibular nerve, nerve roots with somewhat varying density of myelin were observed without any marked scarring. Sparse round

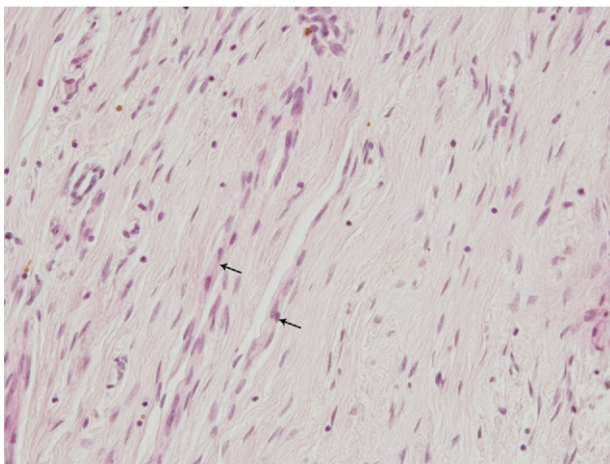


FIGURE 5. Traumatized portion of the left inferior alveolar nerve consisting of collagenous fibrous tissue with slender fibrocyte nuclei and ingrowth of scattered axons with myelin sheaths and Schwann cells (arrows). (Hematoxylin-eosin stain; magnification $\times 20$.)

Eriksson et al. Traumatic Changes After Removal of Third Molar. J Oral Maxillofac Surg 2006.

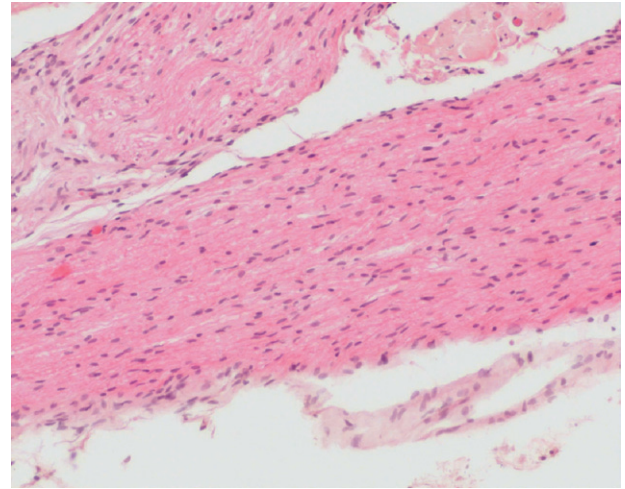


FIGURE 6. Right inferior alveolar nerve showing a normal structure. Compare its dense and regular structure with that of the damaged left nerve portions in Figures 3 through 5. (Hematoxylin-eosin stain; magnification $\times 10$.)

Eriksson et al. Traumatic Changes After Removal of Third Molar. J Oral Maxillofac Surg 2006.

cells were also found without any evidence of regressive changes.

The left Gasserian ganglion showed areas with reduced number of neurones among groups of intact ganglion cells (Fig 9). The right ganglion had abundant intact nerve cells (Fig 10). In the mesencephalon, reduced pigmentation of the locus caeruleus was observed, a finding of possible interest with regard to the patient's depressive state. Pons and medulla were intact.

The histopathological diagnosis was partial destruction and scarring of the inferior alveolar nerve with amputation neuroma and moderate regressive changes in the distal nerve segment.

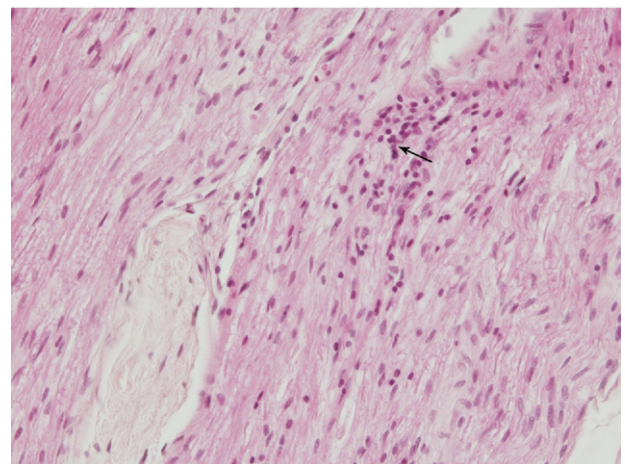


FIGURE 7. Left inferior alveolar nerve with reactive inflammatory hypercellularity in small areas (arrow). (Hematoxylin-eosin stain; magnification $\times 20$.)

Eriksson et al. Traumatic Changes After Removal of Third Molar. J Oral Maxillofac Surg 2006.

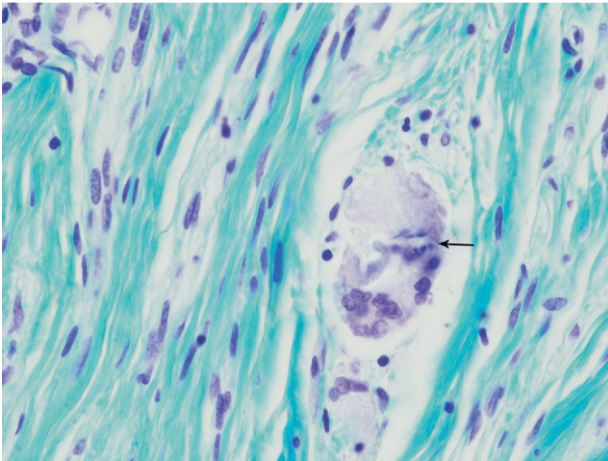


FIGURE 8. Degenerated part of the left inferior alveolar nerve with 2 giant multinucleated cells (arrow) with inclusions of introduced foreign material, bone fragments, a calling card from the visit paid by the surgeon. (Luxol fast blue stain; magnification $\times 40$.)

Eriksson et al. Traumatic Changes After Removal of Third Molar. J Oral Maxillofac Surg 2006.

Discussion

Damage to the inferior alveolar nerve at removal of a lower third molar may result in neuroma-like changes with fascicles, epineural tissue, and axons mixed into the surrounding scar tissue.¹⁰ Such an interruption of the structures of a nerve will result in proliferation of axons, a plausible pathophysiological cause of paresthesia, dysesthesia, allodynia and phantom pain, and it may develop into severe disabling pain.

In our patient, the nerve was dislocated in the area of the alveolus of the third molar. Macroscopically it was somewhat thicker in that area, indicative of neu-

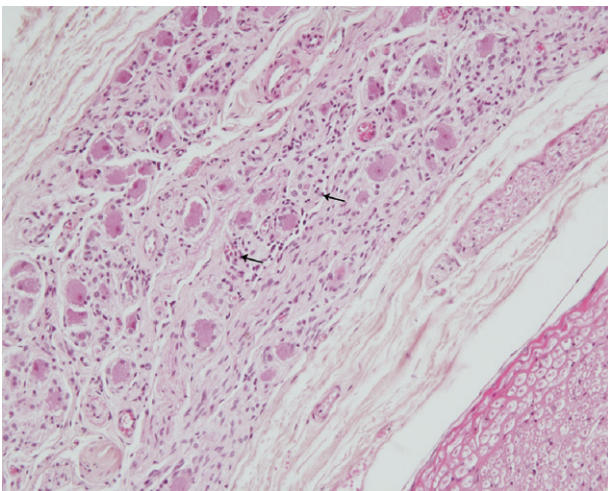


FIGURE 9. Left Gasserian ganglion with areas of reactive hypercellularity (arrows) due to loss of neurones but with some preserved groups of ganglion cells. (Hematoxylin-eosin stain; magnification $\times 20$.)

Eriksson et al. Traumatic Changes After Removal of Third Molar. J Oral Maxillofac Surg 2006.

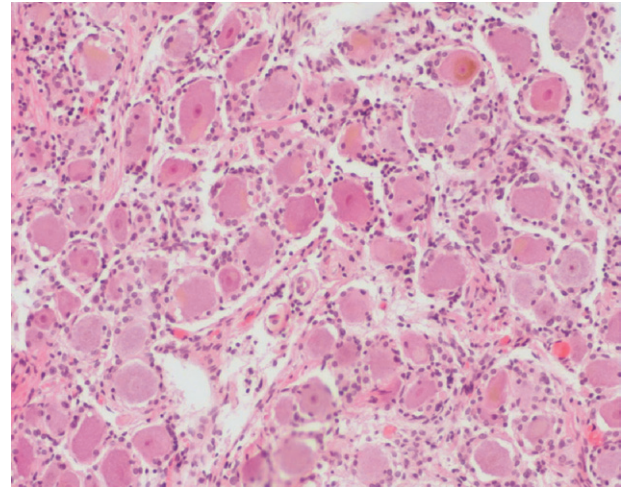


FIGURE 10. Right Gasserian ganglion showing a normal structure with densely and evenly distributed nerve cells. Compare Figure 9 from the left ganglion exhibiting pathological changes. (Hematoxylin-eosin stain; magnification $\times 40$.)

Eriksson et al. Traumatic Changes After Removal of Third Molar. J Oral Maxillofac Surg 2006.

roma in continuity, but the main observation was the changed course. Extirpation of surrounding scar tissue with preserved continuity of the nerve resulted in hypesthesia and a temporary release of the pain that proved to be neurogenic and of peripheral origin. However, a placebo effect of the surgery cannot be excluded and the patient's mental status also may have influenced the experience of the pain.

The significance of the observed morphological changes in the more proximal parts of the nerve for the modulation of the patient's experience of pain and discomfort is not clear. It is known that in addition to peripheral nerve damage, a secondary central affection may occur that continues in spite of peripheral nerve healing. That may lead to so-called deafferentation pain. Such neurogenic, central pain, *anesthesia dolorosa*, is not affected by peripheral surgery/manipulation that may even worsen the situation. A diagnostic nerve block with a local analgesic may indicate whether the site of pain origin is peripheral or central.

On removal of lower third molars close to the alveolar nerve, the risk of severe pain that may be refractory to treatment should be considered if the nerve is damaged. Speculatively, in this case the patient's psychiatric disturbances, as well as the changes in the Gasserian ganglion, may be related to the adverse pain experience.

Acknowledgments

The authors thank Mrs J. Andersson, Department of Forensic Medicine, Lund, Sweden, for valuable help with preparation of histological slides, and Mr J. Greby, Department of Forensic Medicine and LRI Instrument AB, Lund, Sweden for valuable help with micro photos.

References

1. Pogrel MA: The results of microneurosurgery of the inferior alveolar and lingual nerve. *J Oral Maxillofac Surg* 60:485, 2002
2. Meyer RA: Applications of microneurosurgery to the repair of trigeminal nerve injuries. *J Oral Maxillofac Surg* 50:405, 1992
3. Wietholter H, Riediger D, Ehrenfeld M, et al: Results of micro-neurosurgical reconstruction of lingual and inferior alveolar nerve. *Fortschr Kiefer Gesichtschir* 35:128, 1990
4. Blackburn CW: Experiences in lingual nerve repair. *Br J Oral Maxillofac Surg* 30:72, 1992
5. Robinson PP, Loescher AR, Smith KG: A prospective, quantitative study of the clinical outcome of lingual nerve repair. *Br J Oral Maxillofac Surg* 38:255, 2000
6. Donoff RB: Surgical management of inferior alveolar nerve injuries, Part I: The case for early repair. *J Oral Maxillofac Surg* 53:1327, 1995
7. Meyer RA: Applications of microneurosurgery to the repair of trigeminal nerve injuries. *Oral Maxillofac Surg Clin North Am* 4:405, 1992
8. Hillerup S, Hjørting-Hansen E, Reumert T: Repair of the lingual nerve after iatrogenic injury: A follow-up study of the return of sensation and taste. *J Oral Maxillofac Surg* 52:1028, 1994
9. Robinson P, Smith KG: A study of the efficacy of late lingual nerve repair. *Br J Oral Maxillofac Surg* 34:96, 1996
10. Assael LA: The nerve under the microscope (editorial). *J Oral Maxillofac Surg* 60:483, 2002

J Oral Maxillofac Surg
64:1825-1830, 2006

Trans-Geniohyoid Dermoid Cyst: Considerations on a Combined Oral and Dermal Surgical Approach and on Histogenesis

*Jerrold E. Armstrong, BSc, DDS, MSc, FRCD(C),**

Mark R. Darling, BChD, MSc(Dent), MSc(Med), MChD(Path),†

Richard N. Bobay, DMD, MSc, MRCD(C),‡

Graham Cobb, BSc, DDS,§ Danny Lawen, BSc, DDS,¶ and

Tom D. Daley, DDS, MSc, FRCD(C)#

The dermoid cyst of the head and neck occurs most commonly in skin. Rapidis et al¹ found that only 3% of these lesions in children occurred in the floor of the

mouth. Orally, the floor of the mouth is the most common location, although these lesions have been reported in the tongue, lips, and buccal mucosa.² It has been reported in infants and the elderly, but most cases become clinically apparent in adolescents and young adults.³⁻⁶ Both genders may be affected.

Floor of mouth dermoid cysts are slowly enlarging, painless lesions that produce a doughy mass on palpation. They typically occur in the midline and present a more or less symmetrical lesion, although lesions affecting predominantly 1 side are reported.⁴⁻⁷ The location of the cyst relative to the geniohyoid muscle is critical to the clinical presentation. Those lesions presenting above the geniohyoid produce a sublingual swelling that forces the tongue upwards and backwards. Patients with large lesions may suffer dysphagia and/or dysphonia.^{3,5,6} Lesions occurring below the geniohyoid muscle produce a well circumscribed, submental swelling beneath the skin. When a lesion is large enough, a submental mass is clinically visible.^{3,7} Very large lesions may extend through the geniohyoid muscle barrier and produce clinical features in both the sublingual and submental areas.

*Chief of Dentistry, London Health Sciences Centre, London, Ontario, Canada.

†Assistant Professor, Department of Pathology, University of Western Ontario, London, Ontario, Canada.

‡Associate Professor, Oral Radiology, School of Dentistry, University of Western Ontario, London, Ontario, Canada.

§Dental Intern, Dental Department, London Health Sciences Centre, London, Ontario, Canada.

¶Dental Intern, Dental Department, London Health Sciences Centre, London, Ontario, Canada.

#Professor and Chair, Division of Oral Pathology, Department of Pathology, University of Western Ontario, London, Ontario, Canada.

Address correspondence and reprint requests to Dr Daley: Department of Pathology, University of Western Ontario, London, Ontario, Canada N6A 5C1; e-mail: tdaley@fmd.uwo.ca

© 2006 American Association of Oral and Maxillofacial Surgeons

0278-2391/06/6412-0021\$32.00/0

doi:10.1016/j.joms.2006.03.025