



[Authoritative facts](#) about the skin from the [New Zealand Dermatological Society Incorporated](#).

[Home](#) | [Skin lesions](#)

Solar keratoses

Rough scaly spots on sun-damaged skin are called solar keratoses. They are also known as "actinic keratoses". They should be distinguished from other kinds of keratosis (scaly spot) such as [seborrhoeic keratosis](#), [porokeratosis](#) and [keratosis pilaris](#).

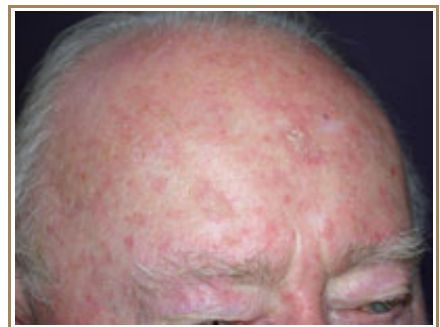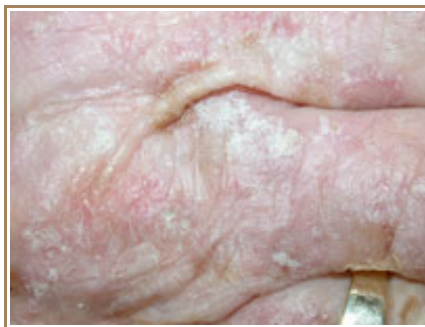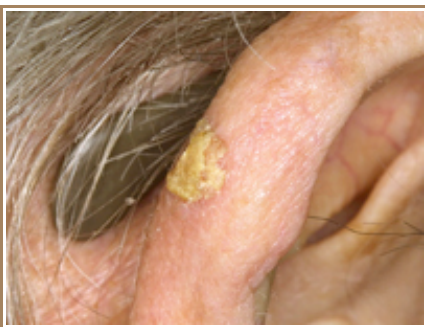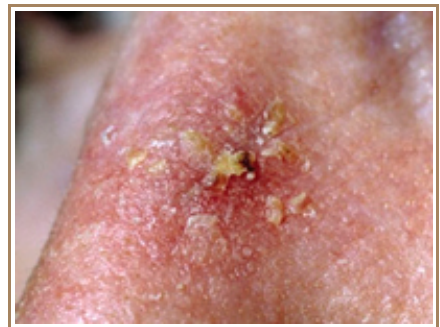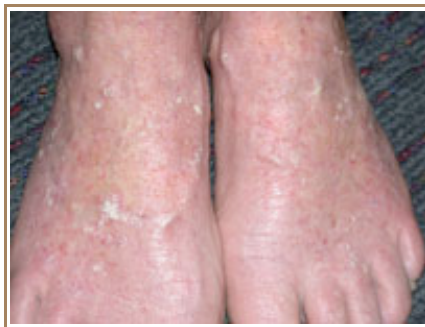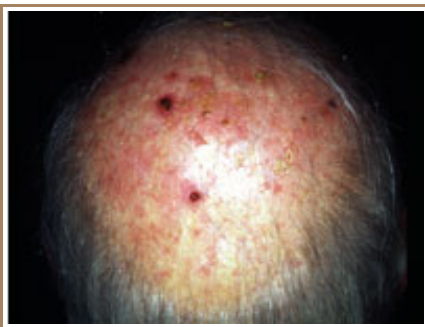
What are solar keratoses?

Solar keratoses are a reflection of abnormal skin cell development due to exposure to ultraviolet radiation. They are considered precancerous.

They appear as multiple flat or thickened, scaly or warty, skin coloured or reddened lesions. A keratosis may develop into a cutaneous horn.

They are very common on sites repeatedly exposed to the sun especially the backs of the hands and the face, most often affecting the nose, cheeks, upper lip, temples and forehead. On the lips they are often called "actinic cheilitis". They are especially common in fair-skinned persons or those who have worked outdoors for long periods without skin protection. Sun-damaged skin is also dry, discoloured and wrinkled.

Solar keratoses



Are solar keratoses dangerous?

Solar keratoses themselves are harmless, but they can be uncomfortable and unsightly.

The main concern is that solar keratoses can give rise to a type of [skin cancer](#) called [squamous cell carcinoma](#). The risk of squamous cell carcinoma occurring in a patient with more than ten solar keratoses is about 10 to 15%.

Solar keratoses are usually removed because they are unsightly or uncomfortable, or because of the risk that skin cancer may develop in them. If a solar keratosis becomes thickened or ulcerated get it checked; it may have become a skin cancer. Squamous cell cancers often look like "volcanoes" erupting within the skin.

People with keratoses should visit their doctor regularly for examination as they are also at risk of developing [basal cell carcinoma](#) and [malignant melanoma](#). Referral to a [dermatologist](#) may be necessary.

Treatment

Treatment of a solar keratosis requires removal of the defective skin cells. New skin then forms from deeper cells which have escaped sun damage.

It is not practical to remove all keratoses in those with very extensive sun damage; in such cases it is important to get rid of thickened or tender lesions as these are the ones at greatest risk of progressing to skin cancer.

Treatments may include:

- **Cryotherapy**
Freezing with [liquid nitrogen](#) causes blistering and shedding of the sun damaged skin. Keratoses treated on the face peel off after about 10 days, those on the hands in about 3 weeks, but those on the legs can take as long as twelve weeks to heal. A light freeze usually leaves no scar, but longer freeze times (necessary for thicker lesions or early skin cancers) result in a pale mark or scar. The lesions may recur in time, in which case they may be retreated by the same or a different method.
- **Curettage & cautery**
[Curettage & cautery](#) may be preferred with thicker keratoses, and is a common method of removing early squamous cell cancers. A specimen is sent for pathological examination. Curettage is the removal of a lesion by scraping it with a sharp instrument. Cautery or diathermy burns the keratoses off and prevents bleeding. A scab forms which heals over a few weeks, leaving a small scar.
- **Excision**
Cutting the lesion out ([excision biopsy](#)) makes sure the lesion has been completely removed, confirmed by pathological examination. This is sometimes important if a lesion may be cancerous. Usually the surgical wound is sutured (stitched). The sutures are removed after a few days, the time depending on the size and location of the lesion. The procedure leaves a permanent scar.
- **5-Fluorouracil cream**
[5-Fluorouracil cream](#) (5-FU, Efudix) is most useful when there are many keratoses on the face. The cream is applied onto facial skin once or twice daily for two to four weeks. The treated areas become red, raw and uncomfortable. Healing starts when the cream is discontinued, and the eventual result is usually excellent.
- **Imiquimod**
[Imiquimod](#) is an immune response modifier in a cream base. It is applied to areas affected by solar keratoses two or three times weekly for four to sixteen weeks. It causes an inflammatory reaction, which is maximal at about three weeks and then gradually settles down with continued use. The results are variable, but generally excellent.
- **Photodynamic therapy**
[Photodynamic therapy](#) (PDT) involves applying a photosensitizer (a porphyrin chemical) to the affected area prior to exposing it to a strong source of visible light. The treated area develops a "burn" and then heals over a couple of weeks or so. [Metvix PDT](#) is available in New Zealand.
- **Diclofenac gel**
Diclofenac in hyaluran gel has been used successfully to treat solar keratoses, and is well tolerated. This product is not available in New Zealand (August 2005).

Prevention of keratoses

Solar keratoses may be prevented by protecting skin from ultraviolet radiation. If already present, keratoses may even improve with regular application of broad spectrum [sunscreen](#) to affected areas every day. [Sun protection](#) is vital for all fair skinned people working or enjoying themselves outdoors.

Related information

On DermNet NZ:

- [Skin cancer](#)
- [Skin lesions](#)

Other websites:

- [ActinicKeratosesNet](#) American Academy of Dermatology
- [Actinic keratoses](#) - emedicine dermatology, the online textbook

Books about skin diseases:

See the [DermNet NZ bookstore](#)

DermNet does not provide an on-line consultation service.

If you have any concerns with your skin or its treatment, see a [dermatologist](#) for advice.

Last updated 26 Dec 2006. © 2007 NZDS. Disclaimer.