

# Orofacial Disease: Update for the Dental Clinical Team: 6. Complaints Affecting Particularly the Lips or Tongue

Crispian Scully and Stephen Porter

**Abstract:** Certain lesions are exclusively or typically found in specific sites; these are discussed in this and the next two articles in this series.

*Dent Update* 1999; **26**: 254-259

**Clinical Relevance:** The lips vary very much between ethnic groups and it is important to know the normal appearance as well as signs of pathological disease.

### Lip Pits

Dimples are common at the commissures but lip pits are uncommon and are distinct pits sited more centrally on either side of the philtrum, ranging from 1 to 4 mm in diameter and depth, present from infancy, often showing a familial tendency and sometimes associated with sinuses or pits on the ears. Rarely they become infected and present as recurrent or refractory cheilitis. Surgical removal may be indicated for cosmetic purposes.

### Cleft Lip

Cleft lip and/or palate are the most common congenital craniofacial abnormalities, and are discussed elsewhere.

### Peutz-Jeghers Syndrome

Peutz-Jeghers syndrome is a rare autosomal dominant trait characterized by discrete, brown to bluish black macules around the mouth, nose and eyes, and polyps in the small intestine which may undergo intussusception or malignant change. Patients with this syndrome are also at increased risk of developing cancer in the gastrointestinal tract, pancreas, breast and reproductive organs.

### Multiple Mucosal Neuroma Syndrome

The rare familial syndrome of multiple endocrine neoplasia type 2b (type-3) is characterized by medullary carcinoma of the thyroid and pheochromocytoma in association with multiple mucosal neuromas. These cause the lips to be thick, slightly everted and have a bumpy surface.

Blisters and spots are the most common complaints affecting the lips. Blisters on the lips are usually caused by herpes labialis but this must be differentiated from carcinoma and other less common causes. In some people, sebaceous glands (Fordyce spots) may be seen as creamy-yellow dots along the border between the vermilion and the oral mucosa. The labial melanotic macule is an acquired small, flat, brown to brown-black asymptomatic benign lesion. Clinically it may resemble other lesions such as early melanoma but it is unchanging in character. Angular stomatitis is a clinical syndrome, in which may be implicated infective agents, mechanical factors, immune deficiency or nutritional deficiencies. Actinic cheilitis is premalignant keratosis of the lip caused by exposure to the sun.

The main complaints of the tongue involve furring or soreness. The tongue is rarely furred in healthy individuals but may be coated with off-white debris in

many illnesses, particularly febrile diseases. Black and brown hairy tongue appears to be caused by the accumulation of epithelial squames and the proliferation of chromogenic micro-organisms. The tongue may be sore for a variety of reasons, but especially because of erythema migrans, lichen planus, glossitis and burning mouth syndrome. Geographic tongue (erythema migrans) is an extremely common condition but of unknown aetiology. Fissured tongue is a common developmental abnormality; its significance is not known but it may be complicated by geographic tongue. Lichen planus and burning mouth (*Dent Update* 1999; **26**: 31-39) were discussed in another article of this series.

The first article presented several general observations on diagnosis and treatment which should be borne in mind in relation to the lesions described here.

### CONGENITAL LESIONS OF THE LIPS

These include:

- Fordyce's spots (discussed in *Dent Update* 1999; **26**: 123-129);
- lip pits;
- cleft lip;
- Peutz-Jeghers syndrome; and
- multiple mucosal neuroma syndrome.

Crispian Scully, PhD, MD, MDS, FDS RCPS, FFD RCSI, FDS RCS, FDS RCSE, FRCPATH, FMed Sci, Professor, and Stephen Porter, PhD, MD, FDS RCSE, FDS RCS, Professor, Eastman Dental Institute for Oral Health Care Sciences, University of London.

<p><b>Inflammatory:</b></p> <ul style="list-style-type: none"> <li>● Infections</li> <li>● Bites</li> <li>● Crohn's disease</li> <li>● Orofacial granulomatosis</li> <li>● Sarcoidosis</li> </ul> <p><b>Traumatic:</b></p> <ul style="list-style-type: none"> <li>● Traumatic or postoperative: <ul style="list-style-type: none"> <li>oedema</li> <li>haematoma</li> <li>surgical emphysema</li> </ul> </li> </ul> <p><b>Immunologically mediated:</b></p> <ul style="list-style-type: none"> <li>● Angioedema</li> </ul> <p><b>Endocrine and metabolic:</b></p> <ul style="list-style-type: none"> <li>● Obesity</li> <li>● Systemic corticosteroid therapy</li> <li>● Cushing's syndrome</li> <li>● Myxoedema</li> <li>● Acromegaly</li> <li>● Nephrotic syndrome</li> </ul> <p><b>Cysts</b></p> <p><b>Hamartomas</b></p> <p><b>Neoplasms</b></p>
--

Table 1. Acquired lip swelling.

## ACQUIRED LIP LESIONS

The causes of labial or orofacial swelling are summarized in Table 1.

### Labial Melanotic Macule (Solitary Labial Lentigo)

The labial melanotic macule is an acquired small, flat, brown to brown-black asymptomatic benign lesion. Clinically it may resemble other lesions such as early melanoma but it is unchanging in character. Most are solitary and seen near the midline, on the lower lip vermilion. They can be hidden by lipstick or excised for cosmetic reasons.

### Blisters

Blisters on the lips may be caused by herpes labialis usually, but other less common causes include:

- burns;
- mucocoeles;
- impetigo;
- allergic cheilitis.

### Herpes Labialis

Herpes was discussed fully in the fourth article of this series (*Dent Update* 1999; **26**: 73-80), and therefore a synopsis only is given here.

HSV, once acquired, remains latent in the trigeminal ganglion. Factors such as fever, sunlight, trauma, menstruation or

immunosuppression can reactivate the virus which is shed into the saliva, and there may be clinical recrudescence, recurrently, to produce herpes labialis. Up to 15% of the population have recurrent HSV infections.

Lesions typically appear at the mucocutaneous junction, starting as macules that rapidly become papular, vesicular, and then pustular. The lesions scab and heal within 7 to 10 days, usually without scarring. Widespread recalcitrant lesions may appear in immunocompromised patients.

Diagnosis is largely clinical though viral culture, immunodetection or electron microscopy are used very occasionally. Assay of serum antibodies is of little help in diagnosis. Penciclovir (1%) or aciclovir (5%) cream, applied in the prodromal stage may help to abort or control lesions in healthy patients; systemic aciclovir or other antivirals may be needed for immunocompromised patients.

### Cheilitis (Inflammation of the Lips)

Cheilitis may arise as a primary disorder of the lips. Alternatively, inflammation extends from nearby skin or, less often, from oral mucosal lesions. There are several forms of cheilitis:

- chapping of the lips;
- angular cheilitis (stomatitis);
- eczematous cheilitis;
- contact cheilitis;
- drug-induced cheilitis;
- infective cheilitis;
- actinic cheilitis.

There are also a number of rarer forms.

### Chapping of the Lips

Chapping is a reaction to adverse environmental conditions, usually exposure to freezing cold or to hot, dry winds. The lips become sore, cracked and scaly. Application of petroleum jelly helps, as does avoidance of the causative conditions.

Desquamation and crusting of the lips may also be caused by:

- dehydration;
- exposure to hot dry winds;
- fever;
- cheilitis;
- erythema multiforme;

- psychogenic causes;
- drugs.

### Angular Stomatitis

Angular stomatitis is inflammation of the skin and labial mucous membrane at the commissures of the lips. A fairly common lesion, it is seen mainly in elderly people.

#### Aetiology

Angular stomatitis is a clinical syndrome, in which several factors may be implicated, alone or in combination.

*Infective Agents.* Oral candidosis causing angular stomatitis is particularly common in people wearing dentures, especially where there is denture-induced stomatitis.

*Candida* is probably the major cause, but staphylococci and other bacteria may be isolated from the lesions. Permanent cure can be achieved only by eliminating the *Candida* beneath the upper denture.

*Mechanical factors.* In a patient with dentures of inadequate vertical dimension, and as a normal consequence of the ageing process, the upper lip overhangs the lower at the angles of the mouth, producing an oblique curved fold and keeping a small area of skin constantly macerated and liable to develop angular stomatitis.

*Immune deficiency.* Angular stomatitis associated with candidosis resistant to therapy may be an early manifestation of an underlying immunological deficiency such as diabetes or HIV infection.

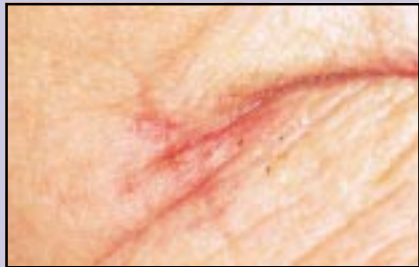*Nutritional deficiency.* Nutritional deficiencies, in particular deficiencies of riboflavin, folate, iron and general protein malnutrition, are occasionally incriminated in angular stomatitis. Riboflavin deficiency produces smooth, shiny red lips associated with angular stomatitis, and this combination has been called *cheilosis*. Crohn's disease or orofacial granulomatosis may be found in some patients.

#### Clinical Features

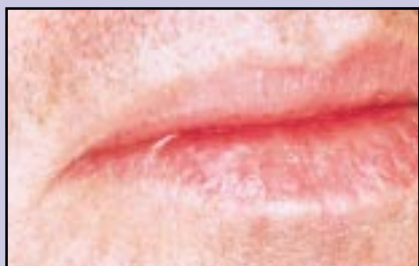Angular stomatitis is typically bilateral (Figure 1), a roughly triangular area of erythema and oedema and persistent. Linear furrows or fissures radiating from the commissures (rhagades) are seen in the more severe forms, especially in denture wearers.

#### Diagnosis and Management

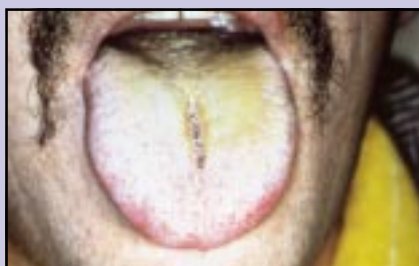Diagnosis is usually obvious clinically. Underlying systemic disease must be sought and treated, especially in young patients, where the lesion is seen in persons



**Figure 1.** Angular cheilitis (bilateral angular stomatitis).



**Figure 2.** Actinic cheilitis.



**Figure 3.** Furred tongue.

without dentures, unilateral cases and patients in whom there are other lesions such as ulcers or glossitis.

In all cases in denture-wearers, *Candida* should be sought, not only in the lesions but also from the denture fitting surface.

Treatment is sometimes difficult and may need to be prolonged. The best solution is often to keep the dentures out of the mouth as much as possible. Dentures should be kept out of the mouth at night and stored in a candidacidal solution such as hypochlorite or chlorhexidine. Denture-induced stomatitis and angular stomatitis should be treated with an anti-fungal agent. Miconazole may be preferable (cream applied locally, together with the oral gel) as it has some Gram-positive bacteriostatic action. However, there is a fairly high relapse rate unless treatment is prolonged, and miconazole is absorbed and may very occasionally potentiate the action of

drugs such as warfarin, phenytoin and the sulphonylureas. Nystatin or amphotericin (as cream or ointment) should therefore be tried first in patients taking these drugs.

Fluconazole is also effective but there are a number of contraindications and potential drug interactions, including with warfarin. Any staphylococcal infection should be treated with fusidic acid ointment or cream at least four times daily.

It may sometimes help to construct new dentures which restore facial contour and normal commissural anatomy. In very rare intractable cases, surgery, or occasionally collagen injections, may be necessary to achieve this.

### Actinic Cheilitis

Also known as actinic keratosis of lip or solar cheilosis, this is premalignant keratosis of the lip caused by exposure to ultraviolet B (UVB) irradiation.

#### Aetiology

Cheilitis due to acute sunburn is common, and clinically resembles 'chapping' of the lips. Particular care is needed to protect the vermilion of the lips with adequate sunscreens in people who are exposed to high levels of UVB, such as mountaineers, wind-surfers, sailors and skiers.

Most actinic cheilitis is seen on the lower lip of fair-skinned men in their fourth to eighth decades of life spending time outdoors in hot, dry regions.

#### Clinical Features

In the early stages there may be redness and oedema; later features include dryness and scaling, vertical fissuring and crusting, development of vesicles and superficial erosions (Figure 2). Later still the epithelium becomes palpably thickened with small greyish-white plaques. Eventually, warty nodules may form and may undergo malignant change.

#### Diagnosis and Management

The diagnosis is clinical but biopsy may be warranted in severe cheilitis and must always be considered when there are suspect features such as:

- ulceration;
- red and white blotchy appearance with an indistinct vermilion border;
- generalized atrophy with focal areas of whitish thickening;
- persistent flaking and crusting.

It may be wise to seek specialist opinion where there is the possibility of malignant change. Treatment, required to relieve symptoms and to prevent development of carcinoma, is with:

- topical 5% fluorouracil three times daily for 10 days, or trichloroacetic acid or tretinoin;
- vermilionectomy (lip shave);
- laser ablation.

Following treatment, the best protection against recurrence is the regular use of a liquid or gel waterproof sunscreen lip salve containing para-aminobenzoic acid.

### Eczematous Cheilitis

The lips are often involved in atopic eczema, but the possibility of contact dermatitis (contact cheilitis) must also be considered. The treatment of atopic eczema of the lips is with emollients and topical corticosteroids; potent steroids such as fludrocortisone may be required.

### Contact Cheilitis

Contact cheilitis is an inflammatory reaction of the lips, provoked by irritant or sensitizing actions of chemicals. It is seen mainly in adult women.

#### Aetiology

Many substances have been implicated, but most cases are caused by contact with:

- lipsticks or lip salves;
- bactericidal agents;
- tartar-control dentifrices, which contain pyrophosphate compounds;
- epimine-containing materials used for temporary crowns and bridges;
- other dental materials;
- items commonly sucked such as metal hair clips, pencils (cobalt paint or metals), etc.;
- nail varnish;
- essential oils, such as eugenol, peppermint, cinnamon, cloves and spearmint in food and other materials;
- wooden and nickel mouthpieces of musical instruments.

#### Clinical Features

There may be persistent irritation and scaling or a more acute reaction with oedema and vesiculation.

**Diagnosis and Management**

The diagnosis is clinical; erythema multiforme may present similarly but patients with the latter usually also have oral or other erosions. If an allergic reaction is suspected, patch tests should be carried out using appropriate concentrations of the substances concerned. Specialist referral may be warranted.

Topical corticosteroids will give symptomatic relief but the offending substance must be traced and avoided.

**Other Lip Lesions**

Other lesions of the lips include swellings caused by:

- oedema (trauma or infection or insect bite);
- angioedema;
- Crohn's disease;
- orofacial granulomatosis;
- sarcoidosis;
- mucoceles;
- tumours;
- abscesses;

and ulceration, caused by:

- trauma;
- herpes labialis;
- burns;
- syphilis;
- other infections;
- tumours.

**LESIONS OF THE TONGUE**

**Furred Tongue**

Furred tongue is a common problem, mainly in adults.

**Aetiology**

The coating appears to be of epithelial, food and microbial debris which collects because it is not mechanically removed. Indeed, the tongue is the main reservoir of some micro-organisms such as *Candida albicans* and some streptococci.

**Clinical Features**

Coating of the tongue is quite commonly seen in healthy adults, particularly in edentulous patients, people eating a soft, non-abrasive diet, with poor oral hygiene, or who are fasting.

The dorsum, particularly posteriorly, may

be coated with off-white debris in many illnesses, especially febrile diseases (Figure 3). The coating appears more obvious in xerostomia and in ill patients, especially those with poor oral hygiene or who are dehydrated.

**Diagnosis and Management**

Exclude other conditions such as thrush (rarely occurs on the dorsum of tongue), chronic candidosis, hairy leukoplakia (lateral borders of tongue) or other leukoplakias.

Treatment of the underlying condition often suffices but it can be useful to brush the tongue to remove the coating. This is best done in the evenings, since brushing early in the morning often leads to retching. It is important also to maintain good oral hygiene.

**Superficial Brown Staining**

Superficial brown discoloration of the tongue and teeth may be caused by cigarette smoking, some drugs (such as iron salts), some foods and beverages (such as coffee and tea), betel and chlorhexidine. Such discoloration is easily removed and is of little consequence.

**Black or Brown Hairy Tongue**

**Aetiology**

Black or brown hairy tongue appears to be caused by the accumulation of epithelial squames and the proliferation of chromogenic micro-organisms. Occasionally, a black hairy tongue may be caused by antimicrobial therapy, especially with broad-spectrum drugs such as tetracyclines or griseofulvin. The latter condition is related to overgrowth of *Candida* species and may respond to withdrawal of the drug. Smoking, drugs (e.g. iron salts) and poor oral hygiene (proliferation of chromogenic micro-organisms, not *Candida albicans*) may predispose.

**Clinical Features**

A brown or black hairy appearance of the central dorsum of tongue, most severe posteriorly (Figure 4). The filiform papillae are excessively long and stained.

**Diagnosis and Management**

Diagnosis is clear-cut. It is important to discontinue any drugs or

mouthwashes responsible.

The condition may be improved by stopping smoking, increasing the standard of oral hygiene, brushing the tongue with a toothbrush (in the evenings; see above), using sodium bicarbonate mouthwashes, chewing pineapple or sucking a peach stone.

**Fissured Tongue**

**Aetiology**

This is a common developmental abnormality, of no known significance. A fissured (scrotal) tongue is found in many normal persons, and often in people with Down's syndrome or Melkersson-Rosenthal syndrome.

**Clinical Features**

Multiple fissures are usually present on the dorsum of the tongue, and may be complicated by geographic tongue (Figure 5).

**Diagnosis and Management**

The diagnosis is usually clear-cut although it must be differentiated from the lobulated tongue seen in Sjogren's syndrome.

Management is to reassure the patient.

**Geographic Tongue**

This condition is also known as erythema migrans or benign migratory glossitis. Red patches that change in size and shape and resemble a map (hence 'geographic') may be seen in persons of all ages but are typically detected in adults.

**Aetiology**

Geographic tongue is an extremely common condition but of unknown aetiology. It has a genetic background and a familial pattern is common. It is associated with psoriasis in 4% of patients.

**Clinical Features**

There are irregular demarcated areas of desquamation mainly on the dorsum of the tongue and, rarely, the adjacent oral mucosa (Figure 6). The red areas are often surrounded by a yellow border. Red areas change in shape, increase in size, and spread or move to other areas within hours. The condition may cause some soreness, especially when acidic foods (e.g. tomatoes) are being eaten. Geographic tongue is often found in

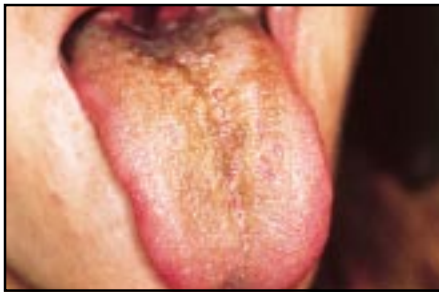

Figure 4. Black hairy tongue.

patients who have a fissured tongue.

**Diagnosis and Management**

The diagnosis is clinical and no investigations are usually needed unless there is the possibility of deficiency glossitis. Some specialists believe geographic tongue to be a form of psoriasis. Very similar lesions may be seen in psoriasis and also in Reiter's syndrome (transiently). There also may be confusion with lichen planus and lupus erythematosus.

The condition is not serious and there is no effective treatment. Patients should, however, be informed about the condition, and reassured (Table 2).

**Foliate Papillitis**

The size and shape of the foliate papillae on the posterolateral margins of the tongue are variable. The papillae occasionally swell if irritated mechanically or if there is an upper respiratory infection. Located at a site of high predilection for lingual cancer, they may give rise to anxiety about cancer

**Glossitis in Deficiency States**

Glossitis is a red, often sore, tongue. It is uncommon.

**Aetiology**

Deficiencies of iron, folic acid, or vitamin B<sub>12</sub> (rarely other B vitamins) are the cause. Iron deficiency is common and usually a consequence of heavy bleeding such as in menorrhagia, or from the gastrointestinal tract. The latter may be due to a peptic ulcer, inflammatory bowel disease, or a malignant neoplasm. Folic acid deficiency is seen mainly where the diet is poor in leafy vegetables. Vitamin B<sub>12</sub> deficiency is uncommon except in people suffering from pernicious anaemia, vegan vegetarians, dietary faddists or malabsorption states. Diseases of the small intestine (such as

coeliac disease) may lead to malabsorption of folic acid and iron; ileal disease such as Crohn's disease may lead to vitamin B<sub>12</sub> malabsorption.

**Clinical Features**

The sore tongue may appear quite normal, or it may be red and depapillated. There may be:

- linear or patchy red lesions (especially in vitamin B<sub>12</sub> deficiency);
- depapillation with erythema—termed glossitis (in deficiencies of iron, folic acid or B vitamins). Lingual depapillation begins at the tip and margins of the dorsum but later involves the whole dorsum;
- pallor (iron deficiency).

There may also be oral ulceration and angular stomatitis.

**Diagnosis and Management**

It is important to differentiate this condition from erythema migrans, lichen planus and acute candidosis.

Treatment is replacement therapy after the underlying cause of the deficiency is established and rectified.

**Glossitis due to Candidosis**

**Aetiology**

Opportunistic infection with *Candida* species, particularly *C. albicans*, may result from predisposing factors such as:

- broad spectrum antimicrobials,

- particularly tetracycline;
- topical corticosteroids;
- xerostomia;
- immune defects.

It is uncommon except in people taking antibiotics or steroids, or infected with HIV.

**Clinical Features**

Diffuse erythema and soreness of tongue are the main findings but there may also be patches of thrush.

**Diagnosis and Management**

Diagnosis is mainly clinical but it can sometimes be helpful to smear for candidal hyphae or to take an oral rinse to assess the degree of candidal infection.

Treatment should first be directed to the predisposing cause. The patient should stop smoking, and be given antifungals.

**Median Rhomboid Glossitis**

**Aetiology**

This was considered to be a developmental lesion but current evidence suggests that it is in fact a candidal lesion. Usually the patient is adult and almost invariably a smoker. A similar lesion may be seen in HIV-infected individuals.

**Clinical Features**

There is a depapillated rhomboidal, usually asymptomatic, area in the centre line of the dorsum of tongue anterior to the circumvallate papillae (Figure 7). The lesion may be flat or nodular, red, or red and white.

**Diagnosis and Management**

The diagnosis is usually made on clinical grounds alone. Biopsy is not usually needed as the location is typical and tumours are rare at this site.

The patient should stop smoking. Antifungals may be indicated but if the lesion fails to clear, laser excision is warranted.

**Tongue Swelling**

Discrete lumps may be of various causes:

- congenital—lingual thyroid, haemangioma, lymphangioma;
- inflammatory—infection, abscess;
- traumatic—oedema, haematoma, foreign body;
- cysts;
- neoplasms—fibrous lump, papilloma,

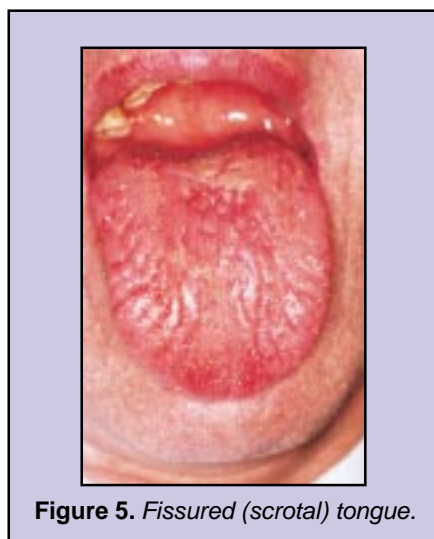


Figure 5. Fissured (scrotal) tongue.

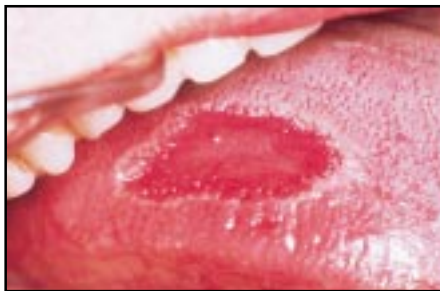

Figure 6. Geographic tongue.

carcinoma, granular cell tumour (granular cell myoblastoma), Kaposi's sarcoma.

Midline lumps in the posterior tongue rarely prove to be due to a lingual thyroid. The neck should be examined and a scan performed to ensure the presence of a normal thyroid before such a lump is excised.

Generalized lingual swelling may be due to:

- Down's syndrome;
- angioma;
- inflammatory oedema;
- angioedema;
- gigantism;
- acromegaly;
- amyloidosis;
- other rare causes.

### Amyloidosis

Amyloidosis is a rare condition characterized by deposition in tissues of an eosinophilic hyaline material, amyloid, which has a fibrillar structure on electron microscopy.

### Aetiology

Amyloid deposits are not all the same. In primary (including myeloma-associated) amyloid they consist of immunoglobulin light chains. In secondary and other forms of amyloid, AA proteins are found. Secondary amyloidosis is now seen mainly in rheumatoid arthritis and ulcerative colitis, and rarely affects the mouth.

### Clinical Features

Oral amyloidosis is almost exclusively seen in primary amyloidosis. Manifestations include macroglossia, in up to 50% of patients, and oral petechiae or blood-filled bullae.

### Diagnosis and Management

Biopsy is required; oral amyloid deposits

may be detected histologically even in the absence of clinically apparent lesions. Congo red or thioflavine T staining of biopsy material is usually required in order to confirm the diagnosis although, in advanced amyloidosis, the deposits may be noted on conventional haematoxylin and eosin staining. Other investigations may include urinalysis (Bence-Jones proteinuria), a blood picture, serum and urine electrophoresis, erythrocyte sedimentation rate and marrow biopsy; and skeletal survey for myeloma. Thus specialist referral is indicated.

Management is of the underlying disease (where present), is difficult, and requires specialist care. Chemotherapy with melphalan, corticosteroids or fluoxymesterone are usually used. Surgical reduction of the tongue is inadvisable because the tissue is friable, often bleeds excessively and the swelling quickly recurs.

### Further Reading

- Brook IM, King DJ, Miller ID. Chronic granulomatous cheilitis and its relationship to Crohn's disease. *Oral Surg Oral Med Oral Pathol* 1983; **56**: 405-407.
- Buchner A, Hansen LS. Pigmented nevi of the oral mucosa. *Oral Surg Oral Med Oral Pathol* 1980; **49**: 55-62.
- Burton J, Scully C. The lips. In: Champion RH, Burton J, Burns DA, Breathnach SM, eds. *Textbook of Dermatology*, 6th ed. Oxford: Blackwells, 1998; pp.3125-3148.
- Chandler K, Chaudhry Z, Kumar N, Barrett AW, Porter SR. Melanocanthoma: a rare cause of oral hyperpigmentation. *Oral Surg Oral Med Oral Pathol Oral Radiol Endod* 1997; **84**: 492-494.
- Eveson JW, Scully C. *Colour Atlas of Oral Pathology*. London: Mosby-Wolfe, 1995.
- Jones JH, Mason DK. *Oral Manifestations of Systemic Disease*, 2nd ed. London: Baillière Tindall, 1980.
- Kaugars GE, Heise AP, Riley WT *et al.* Oral melanotic macules. A review of 353 cases. *Oral Surg Oral Med Oral Pathol* 1993; **76**: 59-61.
- Millard HD, Mason DK, eds. *Perspectives on 1993 World Workshop on Oral Medicine*. Ann Arbor: University of Michigan Press, 1995.
- Reade PC, Sim R. Exfoliative cheilitis—a factitious disorder? *Int J Oral Maxillofac Surg* 1986; **15**: 313-317.

- This is a common condition
- The cause is unknown
- It may be inherited from parents
- It is not thought to be infectious
- It is rarely associated with psoriasis
- It has no long-term consequences
- There is no reliably effective treatment

Table 2. Patient information sheet for geographic tongue.

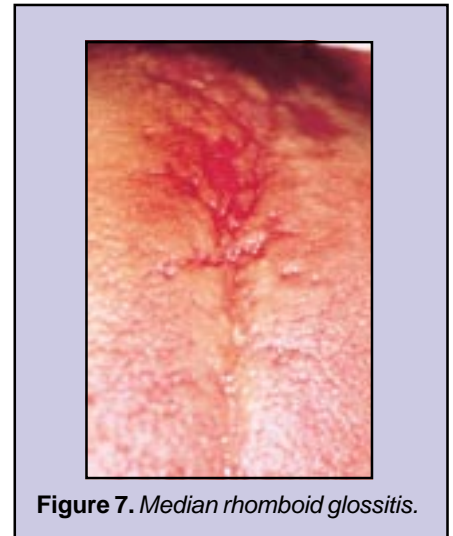

Figure 7. Median rhomboid glossitis.

- Reinish EI, Raviv M, Srolovitz H *et al.* Tongue, primary amyloidosis and multiple myeloma. *Oral Surg Oral Med Oral Pathol* 1994; **77**: 121-125.
- Rodu B, Martinez MG. Peutz-Jeghers syndrome and cancer. *Oral Surg Oral Med Oral Pathol* 1984; **58**: 584-588.
- Scully C. *Handbook of Oral Diseases*. London: Martin Dunitz, 1999.
- Scully C, Bagan JV, Eisen D, Porter SR, Rogers RS. *Dermatology of the Lips*. Oxford: Isis Medical, 1999.
- Scully C, Cawson RA. *Medical Problems in Dentistry*, 4th ed. Oxford: Butterworth-Heinemann, 1998.
- Scully C, Flint S, Porter S. *Oral Diseases*. London: Martin Dunitz, 1996.
- Scully C, Welbury R. *Colour Atlas of Oral Disease in Children and Adolescents*. London: Mosby-Wolfe, 1994.
- Scully C. The pathology of orofacial disease. In: Barnes IE, Walls AWG, eds. *Gerodontology*. Oxford: Wright, 1994; pp.29-41.
- Scully C, Porter SR. Oral mucosal disease: a decade of new entities, aetiologies and associations. *Int Dent J* 1994; **44**: 33-43.
- Scully C. Diagnosis and diagnostic procedures: general and soft tissue diagnosis. In: *Pathways in Practice*. London: Faculty of General Dental Practice, Royal College of Surgeons of England, 1993; pp.25-33.
- Scully C. Prevention of oral mucosal disease. In: Murray JJ, ed. *Prevention of Oral and Dental Disease*, 3rd ed. Oxford: Oxford University Press, 1995; pp.160-172.
- Scully C. The oral cavity. In: Champion RH, Burton J, Ebling FJG, eds. *Textbook of Dermatology*, 5th ed. Oxford: Blackwells, 1991; pp.2689-2769.
- Scully C. The oral cavity. In: Champion RH, Burton J, Burns DA, Breathnach SM, eds. *Textbook of Dermatology*, 6th ed. Oxford: Blackwells, 1998; pp.3047-3124.
- van der Wal N, van der Kwast WA, van der Waal I. Median rhomboid glossitis: a follow-up of 16 patients. *J Oral Med* 1986; **41**: 117-120.
- Winchester L, Scully C, Prime SS *et al.* Cheilitis glandularis: a case affecting the upper lip. *Oral Surg Oral Med Oral Pathol* 1986; **62**: 654-657.