

Nerve Damage and Third Molar Removal

A. R. LOESCHER, K. G. SMITH AND P. P. ROBINSON

Abstract: The surgical removal of lower third molars endangers both the lingual and inferior alveolar nerves. Patients sustaining an injury to either of these nerves must be managed correctly, and this requires a diagnosis of the injury type and regular monitoring of the recovery of sensation. Surgical intervention for a damaged inferior alveolar nerve is not usually indicated but may be undertaken: if the nerve is completely divided and the severed ends are misaligned; if a bony fragment has compressed the mandibular canal; or if the patient suffers from persistent neuropathic pain. In contrast, after injury to the lingual nerve, if sensory testing demonstrates no neural recovery within 3–4 months, exploration of the injury site and microsurgical repair of the damaged nerve is indicated.

Dent Update 2003; 30: 375–382

Clinical Relevance: It is imperative that patients sustaining a nerve injury are managed correctly and this must include a diagnosis of the type of injury, monitoring recovery and the treatment of appropriate cases.

Impacted mandibular third molar teeth are in close proximity to the lingual, inferior alveolar, mylohyoid and buccal nerves (Figure 1). During surgical removal, each of these nerves is at risk of damage, but the most troublesome complications result from inferior alveolar or lingual nerve injuries. The majority of injuries result in transient sensory disturbance but, in some cases, permanent paraesthesia (abnormal sensation), hypoesthesia (reduced sensation) or, even worse, some form of dysaesthesia (unpleasant abnormal sensation) can occur (Table 1). These sensory disturbances can be troublesome causing problems with

speech and mastication and may adversely affect the patient's quality of life. They also constitute one of the most frequent causes of complaints and litigation. It is therefore imperative that patients sustaining nerve injuries are managed correctly, and this includes correct diagnosis of the type of injury, monitoring recovery, and the treatment of appropriate cases.

The characteristics of the inferior alveolar, lingual and buccal nerves, and the likely incidence of damage, will now be discussed. Injury to the mylohyoid nerve is rare and is not considered further in this brief update.

INFERIOR ALVEOLAR NERVE

The inferior alveolar nerve is morphologically unusual in that it travels a significant distance within bone in the mandible. In the mandibular canal it is supported by the surrounding

connective tissue and other structures in the neurovascular bundle. After injury, unless the nerve is displaced into the socket, the severed nerve ends do not retract, but will remain in apposition. Regeneration within the canal will thus be unimpeded unless obstructed by displaced fragments of bone from the roof of the canal. Good recovery after injury would therefore be expected.

Many studies have reported the frequency of nerve injury during the removal of third molars (for review see Robinson 1997¹) and most indicate that inferior alveolar nerve function is disturbed after 4–5% of procedures (range 1.3–7.8%). Most patients will regain normal sensation within a few weeks or months and less than 1% (range 0–2.2%) have a persistent sensory disturbance.

The anatomical relationship between

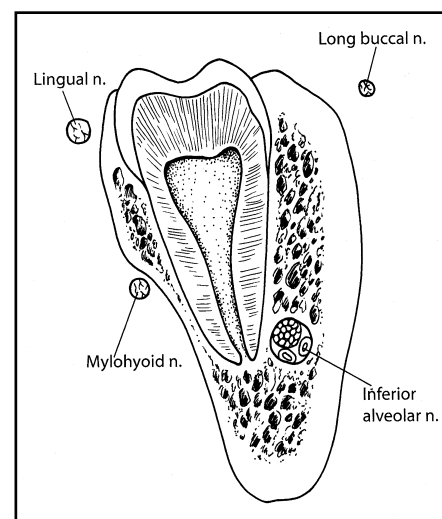


Figure 1. Cross-section of the mandible through the third molar showing the inferior alveolar, lingual, mylohyoid and long buccal nerves.

A.R. Loescher, BDS, PhD, FDS RCS, MBChB,
K.G. Smith, BDS, PhD, FDS RCS and
P.P. Robinson, BDS, PhD, FDS RCS, DSc, FMedSci,
Department of Oral and Maxillofacial Surgery,
School of Clinical Dentistry, Claremont Crescent,
Sheffield S10 2TA.

Anaesthesia	Absence of all sensory modalities.
Hypoaesthesia	Diminished sensitivity to stimulation, excluding special senses.
Paraesthesia	An abnormal sensation, whether spontaneous or evoked.
Dysaesthesia	Unpleasant abnormal sensation, whether spontaneous or evoked.
Hyperalgesia	An increased response to a stimulus that is normally painful.
Allodynia	Pain due to a stimulus that does not normally provoke pain.

Table 1. Pain terms adapted from the definitions of the International Association for the Study of Pain (www.iasp-pain.org).

the inferior alveolar nerve and the roots of the third molar may be judged radiographically^{2,3,4,5} in an attempt to predict the likelihood of nerve damage. Rood and Shehab (1990)⁵ identified five radiographic features that were related to inferior alveolar nerve injury and these are listed in Figure 2. The same study failed to show that ‘narrowing of the inferior alveolar canal’ and the ‘presence of a dark and bifid apex’ were significant predictors of inferior alveolar nerve injury; features that had previously been considered important.⁶ Paradoxically, sensory disturbance may occur following removal of teeth that show none of these features, and may not occur even when there appears to be clear evidence of a close relationship between the canal and the tooth roots.

A higher incidence of inferior alveolar nerve injury has been reported with third molars that are horizontally^{3,7} or mesioangularly⁴ impacted and have complete bone cover.⁷ One study has also demonstrated that increasing age is associated with a higher frequency of inferior alveolar nerve injury (14–24 year-old patients 1.2%; 35–81 year-old patients 9.7%).⁸

LINGUAL NERVE

The lingual nerve is morphologically very different from the inferior alveolar nerve. At the usual site of injury (adjacent to the lower third molar) the nerve is covered with only a thin layer of soft tissue and mucosa, rather than being in a bony canal. Consequently, if sectioned, the cut nerve ends retract apart and, if the adjacent soft tissue is also distorted, the nerve ends may become misaligned and

trapped or constricted by scar tissue. Regeneration of axons across a gap will be less successful than if the nerve ends remain in apposition. In addition, the presence of a range of functionally distinct nerve fibre types in this nerve (e.g. mechanosensitive, thermosensitive, gustatory, vasomotor and secretomotor) may make successful regeneration of the axons back to the correct receptor/effector and location less likely (see below).

There is a wide range in the reported frequency of lingual nerve injuries during third molar removal, with 0.2–22% of patients reporting sensory disturbances in the early post-operative period and 0–2% a permanent disturbance (for review see Robinson 1997¹). There are several possible explanations for the wide range in incidence. First, the variation may reflect differences in the time interval between tooth removal and the assessment of the sensory impairment; early assessments will report many transient sensory changes that recover rapidly and completely, and which would be missed if assessment takes place after a longer recovery period. Secondly, the incidence of nerve injury may depend upon whether the sensory deficit was established objectively by the clinician or was based on a subjective patient assessment. Finally, it may reflect differing surgical techniques; several studies have shown that the raising and retraction of a lingual mucoperiosteal flap is associated with an increased frequency of lingual nerve damage.^{9,10} Two recent studies and a systematic review have concluded that raising and retracting a lingual periosteal flap is not necessary¹¹ and is best avoided.^{12,13}

In addition to the surgical technique, other risk factors have been identified. Lingual nerve damage is particularly associated with deeply impacted teeth when the surgery is consequently difficult, particularly if distal bone removal is required.^{9,10} The results of studies comparing the incidence of lingual nerve injury during surgery utilizing bone removal with burs or chisels are unclear.^{9,10} It is possible that the elevation of a lingual mucoperiosteal flap when chisels are utilized is of more importance than the method of bone removal itself. A recently published prospective study undertaken by Renton and McGurk¹⁴ reported that factors reflecting the surgical skill (i.e. lingual plate perforation) and the difficulty of the extraction were the strongest predictors of temporary and permanent lingual nerve injury.

BUCCAL NERVE

This nerve descends between the two parts of the lateral pterygoid muscle, medial to the ramus of the mandible, and then passes laterally across the external oblique ridge distal to the third molar, to supply the cheek.¹⁵ The sensory distribution is variable but includes the lower posterior buccal sulcus and

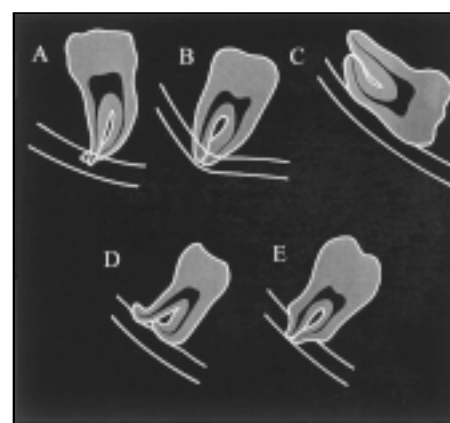


Figure 2. Five radiographic signs suggesting juxtapposition of the mandibular canal to the third molar roots, as described by Rood and Shehab 1990.⁵ Signs significantly related to nerve injury: A. Radiolucency across the roots of the third molar; B. Deviation of the mandibular canal; C. Interruption of the white line of the canal. Signs considered to be clinically important: D. Deflection of the third molar roots by the canal; E. Narrowing of the third molar root.




Figure 3. Sunderland's classification of the five degrees of nerve injury. A. Conduction block; B. Transection of the axon with an intact endoneurium; C. Transection of the nerve fibre (axon and endoneurial sheath) inside an intact perineurium; D. Transection of nerve fibres and perineurium, nerve trunk continuity being maintained by epineurial tissue; E. Transection of the entire nerve trunk. Modified from Sunderland.²¹

gingivae, and an area of cheek mucosa.¹⁶ As the nerve crosses the external oblique ridge it is composed of between one and five branches, the lowest of which may be over 1 cm below the deepest concavity of the ridge.¹⁷ Therefore, part or all of the nerve is at risk when the distal relieving incision is made during third molar surgery. Small areas of sensory disturbance may go unnoticed¹⁸ but a few patients complain of complete anaesthesia of the cheek; the incidence of this complication has not been reported.

CLASSIFICATION OF NERVE INJURY

The consequences and subsequent recovery following nerve damage are dependent upon the severity of the injury, and this is the basis for the classifications of nerve injury proposed by Seddon¹⁹ and Sunderland.²⁰ The latter

classification is valuable as it emphasizes the importance of each structural component of the nerve trunk (Figure 3).²¹ Each of the five degrees of nerve injury, described by Sunderland, may be created during the removal of an impacted third molar tooth:

- Compression injuries (Figure 3A) may occur during the elevation of a third molar with roots in close proximity to the mandibular canal. Minor compression of the nerve, or first degree injuries, will give rise to a temporary conduction block, which is referred to by Seddon¹⁹ as neurapraxia.
- More severe compression or crush injuries (Figure 3B) cause the axon distal to the site of the injury to degenerate (Wallerian degeneration) and recovery of sensation is dependent upon regeneration of the damaged axons. Seddon¹⁹ refers to this second degree injury as axonotmesis.
- Stretch injuries could occur, for example, when raising a lingual mucoperiosteal flap, and could give rise to rupture of the endoneurium and perineurium to produce third or fourth degree injuries (Figures 3C and D), respectively.
- Complete section of the nerve trunk or fifth degree injuries (Figure 3E), referred to by Seddon¹⁹ as neurotmesis, may occur if the inferior alveolar nerve penetrates the root of a third molar and is severed during tooth removal.
- Many nerve injuries that do not fit neatly into this classification and are more complicated. For example, a rotating bur may not only partially divide the lingual nerve but also stretch the nerve. Inflammation around the nerve, caused by infection or foreign bodies, may also alter neural function and increase the pain experienced.²²

SEQUELAE OF NERVE INJURY

Temporary block of nerve conduction (1st degree injury) may be accompanied by some local thinning of the axons and

segmental demyelination, but these changes are reversible.²¹ Recovery of sensation normally occurs within a few days of the surgical trauma, although recovery may be slightly slower if segmental demyelination takes place.²³

The cellular events that follow axonal discontinuity (2nd to 5th degree injuries) have been studied extensively^{21,24} and are summarized in Figure 4. Wallerian degeneration occurs distal to the site of the injury and usually extends centrally for a few millimetres.²⁵ This axonal degeneration consists of disintegration of both the axon and myelin, phagocytosis of the debris by the macrophages and Schwann cells, and

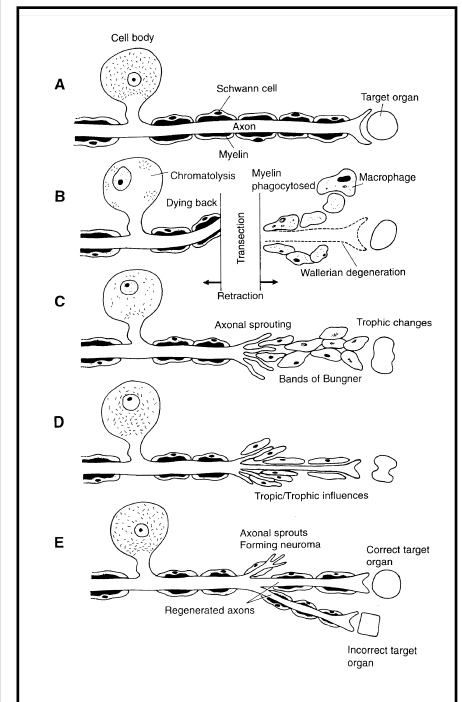


Figure 4. A diagrammatic representation of the cellular events which follow axonal discontinuity of a myelinated trigeminal nerve fibre. A. Normal appearance. B. Transection of the nerve fibre peripherally results in distal fragmentation of the axon and the myelin. In the proximal segment degeneration occurs to at least the first node of Ranvier. C. Schwann cells in the distal stump form the bands of Büngner through which the axon sprouts regenerate. D. The regenerated axon regains contact with the periphery and matures, but a reduction in diameter persists. E. If the cut ends of the nerve are widely separated, it is less likely that good recovery will occur and abnormalities may persist. Sprouts may locate and innervate inappropriate targets or, if no target organ is located, axonal sprouts may persist as a neuroma. Modified from Holland and Robinson.²⁴

then proliferation of the Schwann cells within the endoneurial sheath to form the bands of Büngner. Central to the site of the injury, the rest of the neurone undergoes chromatolytic changes from which it may or may not recover. Regeneration of the axons that survive occurs after an initial delay, which includes a recovery period and the time needed for growth of the axon as far as the injured zone. There is then a delay during which the regenerating fibres cross the injured zone. The initial delay prior to regeneration, and the success of axons in crossing the injury site, is dependent upon the nature of the injury. Crush injuries will recover more rapidly than section injuries as the endoneurial sheaths usually remain intact and therefore the regenerating axons are guided back to the correct receptor type at the correct location.²⁶ In contrast, after nerve section injuries, the regenerating axons enter the endoneurial sheaths of the distal stump, apparently at random, and may be guided to an inappropriate receptor at a new location. This may give rise to abnormalities in localization and the sensation perceived in response to a particular stimulus. Recovery from crush injuries may take months and may not be complete. Recovery from nerve section injuries will progress for at least a year and will never be complete.

METHODS USED TO MONITOR NERVE RECOVERY

Most cases of nerve damage during wisdom tooth removal are not identified at the time of third molar removal but in the post-operative period. The degree of injury is therefore unknown and it is essential both to assess residual function and monitor subsequent recovery to form a judgement as to whether or not the nerve is likely to recover spontaneously, or if surgical intervention will be required. If there is only partial sensory loss, this usually suggests that there has been a first degree injury, and complete recovery is likely. If there is complete anaesthesia in the early period after the injury, it is impossible to determine whether this has been caused by a crush or section injury.

However, careful monitoring of sensory recovery over a three month period should distinguish between these different types of injury.

Monitoring sensory recovery is undertaken by the application of stimuli to the denervated area. Responses of the patient will indicate first the arrival of the regenerating axons and then subsequently the level of recovery. However, the most sensitive indicator of a sensory abnormality is the patient's own subjective report, as minor sensory disturbances may not be detected by testing.

Simple Sensory Testing

A standard protocol for sensory testing does not exist, but a series of simple tests are outlined below. The patient should be seated in a quiet room with both the patient and examiner comfortable. Tests should be undertaken with the patient's eyes closed and the detection of a stimulus is indicated to the examiner by the patient raising a finger. The results of each test are then compared with the normal (uninjured) side. Ideally, the first sensory tests should be undertaken within two weeks of the injury in order to establish a base-line from which to monitor changes. Unfortunately, the equipment needed to perform some of these tests is not readily available and must be constructed by individual clinicians.²⁷

Light Touch Sensation

Light touch is most commonly tested by gently applying a wisp of cotton wool to the skin or mucosa. However, it is difficult to apply this stimulus in a reproducible manner and the use of a cotton wool wisp on moist oral mucosa is difficult. Greater consistency and reproducibility can be obtained using Von Frey hairs and the method of making these instruments with a standard force of 20 mN (2g) has been described.²⁷ Stimuli are applied at random and the area of anaesthesia can be mapped by moving outwards in small steps until the stimulus is felt.

Pin prick sensation

Testing pin prick threshold is often

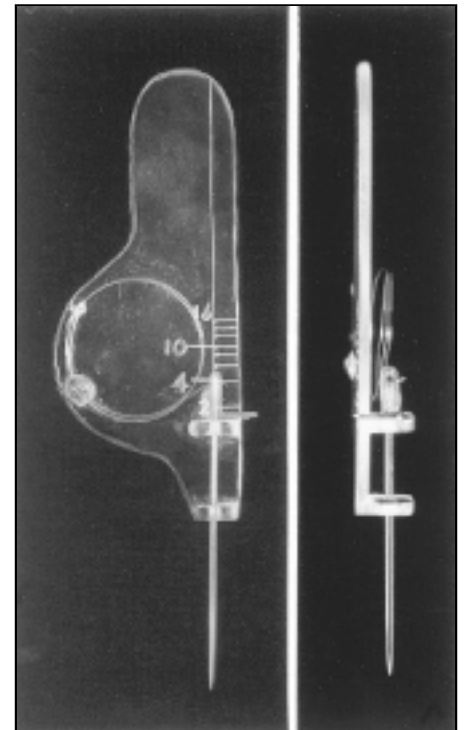


Figure 5. An instrument used to apply pin prick stimuli with calibrated pressures of up to 150mN (15g).

performed using a dental probe or needle, but again reproducibility is poor. A simple device, described by Sunderland,²¹ overcomes this difficulty. A pin is attached to a spring, which allows it to be applied at a known pressure of up to 150 mN (15 g) (Figure 5). Initially, stimuli of up to 150 mN can be applied randomly over the test areas to determine whether or not any sensation is perceived. In this way, areas of anaesthesia can be mapped. If sensation is present within the affected area on the injured side, then the *pin prick sensation threshold* is determined. For this test the pin is applied at steadily increasing pressures and the patient asked to indicate the point at which the sensation becomes sharp rather than dull. The pin prick sensation threshold is noted for a series of randomly chosen points on both the injured and the uninjured side.

Two Point Discrimination

This test can quickly be performed if pairs of blunt probes with different separations (2–20 mm) are mounted around a disc (Figure 6).²⁷ The probes are applied at a series of fixed sites

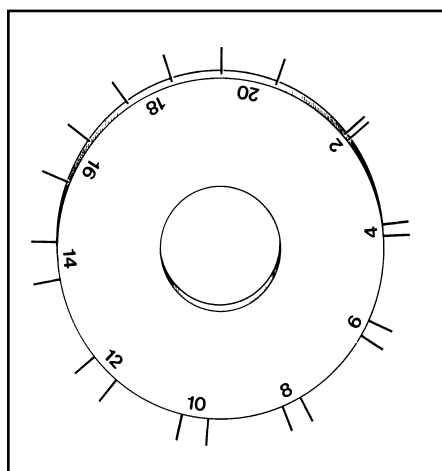


Figure 6. A simple device for rapid two point discrimination testing.

chosen on the lips or tongue, depending on which has been damaged. The probes are drawn a few millimetres across the surface, at a constant pressure, and the patient is asked whether one or two points are felt. The minimum separation, that is consistently reported as two points, is termed the two point discrimination threshold. This threshold varies in different regions of the mouth (2–4 mm on the tongue and lip, 8–10 mm on the skin over the lower border of the chin).

Taste Stimulation

Lingual nerve injury will result in taste loss from the ipsilateral anterior segment of the tongue. Although taste testing may not be undertaken routinely, it is simple to perform. Cotton wool pledgets soaked in 1M sodium chloride, 1M sucrose, 0.4M acetic acid or 0.1M quinine are drawn 1–2 cm across the lateral border of the tongue and the patient asked to indicate whether they taste salt, sweet, sour, bitter or no taste, before replacing the tongue in the mouth. Stimuli should be applied in random order, to each side of the tongue, and rinsing with tap water between tests is permitted.

TREATMENT

A flow chart showing a protocol for the management of inferior alveolar and lingual nerve injuries is shown in Figure 7.

Inferior alveolar nerve

If an inferior alveolar nerve passes through the roots of a wisdom tooth and is accidentally divided at the time of surgery, repair is indicated if the nerve ends do not remain in apposition within the canal. This should ideally be performed at the same time as the tooth removal, but if this is not possible the patient should be referred urgently to an appropriate maxillofacial unit.

If a sensory disturbance is first noted at review, recovery should be monitored using the sensory tests described above. Patients with paraesthesia in the distribution of the inferior alveolar nerve (evoked by touching the lip or chin) usually require no surgical intervention. Patients with complete anaesthesia post-operatively should be evaluated radiographically to ensure that the roof of the mandibular canal has not been displaced inferiorly to create an obstruction to regeneration.¹⁸ In the extremely rare event that this has occurred, removal of the bony fragment would seem to be appropriate, without undue delay. Referral to a maxillofacial surgeon familiar with this type of procedure is important. The patient should also be informed that complete recovery may not follow this procedure and that some recovery may occur even if surgical ‘decompression’ is not performed.

If, by 3 months after the injury, monitoring reveals little or no sensory recovery, referral is again indicated. A further radiograph to assess the continuity of the mandibular canal is obtained, and surgical exploration and ‘decompression’ of the nerve is considered if the canal is disrupted, if there is very little recovery of sensation, or if there is significant dysaesthesia.²⁸ However, the results of surgery are variable and sometimes disappointing.

Lingual Nerve

A lingual nerve that is knowingly transected during wisdom tooth removal should be immediately repaired using epineurial sutures. Again, this may not be possible in practice, and immediate

referral to an appropriate experienced maxillofacial surgeon is indicated. In the majority of patients, the injury is only discovered post-operatively.

At early review, the presence of some sensation in response to stimulation of the tongue suggests that the nerve is at least partially intact; no treatment is indicated but sensory monitoring is required. As described above, complete anaesthesia could be caused by both a crush or section injury, and so surgical intervention is not indicated initially. However, the absence of progressive sensory recovery by 3–4 months post injury is an indication for surgical exploration at an appropriate maxillofacial unit. If, at the time of surgery, the nerve is found to be intact and of fairly uniform thickness but merely constricted by scar tissue, it should be freed (external neurolysis) and the wound closed. This is unusual, however, and more commonly the nerve is found to have been divided.²⁹ If a neuroma has developed, this can be seen as a marked expansion at the site of the injury and must be excised, together with the damaged segment of the nerve. The severed ends of the nerve can then be mobilized and repair of the nerve should be performed using 8/0 or 9/0 epineurial sutures. A segment of 10–15 mm in length can be excised without causing excessive tension at the repair site and without the need for any form of nerve graft. The results of surgery are very variable; some patients regain good sensation, while others show little if any improvement. However, the multicentre retrospective study of LaBlanc & Gregg³⁰ revealed a success rate of 80% and a recent prospective study has shown that the majority of patients consider the surgery worthwhile.²⁹ Surgery should therefore be offered to all patients with lingual nerve injury who show few signs of spontaneous recovery.

REFERENCES

1. Robinson PP. Nerve injuries resulting from the removal of impacted teeth. In: *Textbook and Colour Atlas of Tooth Impaction*. Andreasen JO, Peterson JK, Laskii DM, eds. Pub. Munksgaard, 1997; pp.469–490.
2. Howe GL, Poyton HG. Prevention of damage to the inferior dental nerve during the extraction

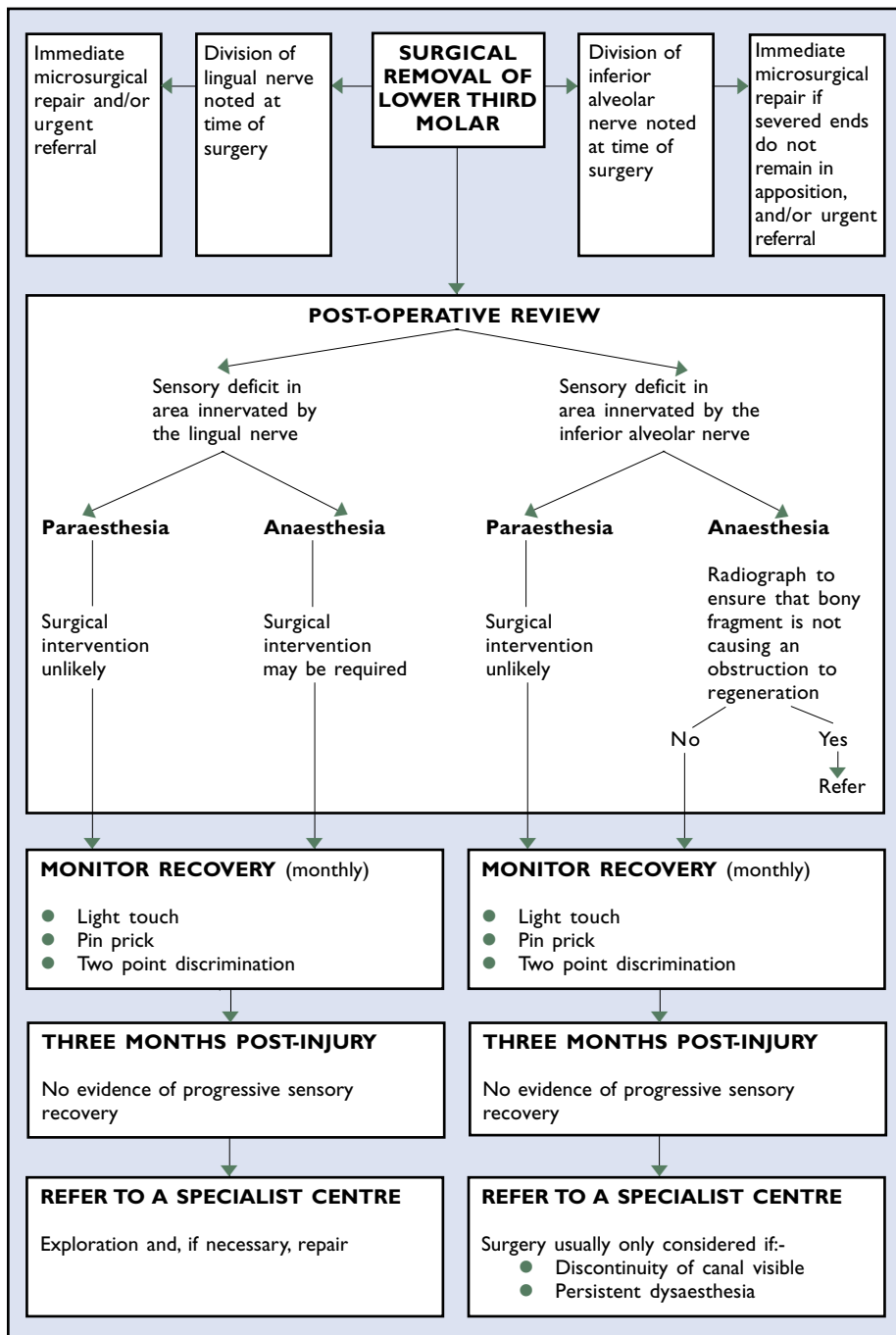


Figure 7. A chart showing a protocol for the management of patients who sustain injury to the inferior alveolar or lingual nerves during lower third molar removal.

of mandibular third molars. *Br Dent J* 1960; **109**: 355–363.

- Kipp DP, Goldstein BH, Weiss WW. Dysesthesia after mandibular third molar surgery: a retrospective study. *J Am Dent Assoc* 1980; **100**: 185–192.
- Wofford DT, Miller RI. Prospective study of dysesthesia following odontectomy of impacted mandibular third molars. *J Oral Maxillofac Surg* 1987; **45**: 15–19.
- Rood JP, Shehab BAAN. The radiological prediction of inferior alveolar nerve injury during third molar surgery. *Br J Oral Maxillofac*

- Surg* 1990; **28**: 20–25.
- Seward GR. Radiology in general dental practice: VIII – Assessment of lower third molars. *Br Dent J*. 1963; **115**: 45–51.
- Carmichael FA, McGowan DA. Incidence of nerve damage following third molar removal: a West of Scotland Oral Surgery Research Group study. *Br J Oral Maxillofac Surg* 1992; **30**: 78–82.
- Bruce RA, Frederickson GC, Small GS. Age of patients and morbidity associated with mandibular third molar surgery. *J Am Dent Assoc* 1980; **101**: 240–245.
- Mason DA. Lingual nerve damage following

- lower third molar surgery. *Int J Oral Maxillofac Surg* 1988; **17**: 290–294.
- Blackburn CW, Bramley PA. Lingual nerve damage associated with the removal of lower third molars. *Br Dent J* 1989; **167**: 103–107.
- Gargallo-Albiol J, Buenechea-Imaz R, Gay-Escoda C. Lingual nerve protection during the surgical removal of lower third molar. A prospective randomised study. *Int J Oral Maxillofac Surg* 2000; **29**: 268–271.
- Robinson PP, Smith KG. Lingual nerve damage during third molar removal. A comparison of two surgical methods. *Br Dent J* 1996; **180**: 456–461.
- Pichler W, Beirne OR. Lingual flap retraction and prevention of lingual nerve damage associated with third molar surgery: A systematic review of the literature. *Oral Surg Oral Med Oral Pathol Oral Radiol Endod* 2001; **91**: 395–401.
- Renton T, McGurk M. Evaluation of factors predictive of lingual nerve injury in third molar surgery. *Br J Oral Maxillofac Surg* 2001; **39**: 423–428.
- Williams PL. In: *Gray's Anatomy*, 38th ed. London: Churchill Livingstone, 1995: p.1237.
- Hendy CW, Robinson PP. The sensory distribution of the buccal nerve. *Br J Oral Maxillofac Surg* 1994; **32**: 384–386.
- Hendy CW, Smith KG, Robinson PP. Surgical anatomy of the buccal nerve. *Br J Oral Maxillofac Surg* 1996; **34**: 457–460.
- Merrill RG. Prevention, treatment, and prognosis for nerve injury related to the difficult impaction. *Dent Clin North Am* 1997; **23**: 471–488.
- Seddon HJ. Three types of nerve injury. *Brain* 1943; **66**: 237–288.
- Sunderland S. A classification of peripheral nerve injuries producing loss of function. *Brain Res* 1951; **74**: 491–516.
- Sunderland S. *Nerves and Nerve Injuries*, 2nd ed. London: Churchill Livingstone, 1978; pp.133–141.
- Tal M. A role for inflammation in chronic pain. *Curr Rev Pain* 1999; **3**: 440–446.
- Ochoa J, Danta G, Fowler TJ. Nature of the nerve lesion caused by a pneumatic tourniquet. *Nature* 1971; **233**: 265–266.
- Holland GP, Robinson PP. Peripheral nerve damage and repair. In: *Clinical Oral Science*. Harris M, Edgar M, Meghji S, eds. Wright, 1998; pp. 274–289.
- Lubinska L. Region of transition between preserved and regenerating parts of myelinated nerve fibres. *J Comp Neurol* 1979; **113**: 315–335.
- Horch KW. Guidance of regrowing sensory axons after cutaneous nerve lesions in the cat. *J Neurophysiol* 1979; **42**: 1437–1449.
- Robinson PP, Smith KG, Johnson FP, Coppins DA. Equipment and methods for simply sensory testing. *Br J Oral Maxillofac Surg* 1992; **30**: 387–389.
- Labanc JP, Van Boven RW. Surgical management of inferior alveolar nerve injuries. *Oral Maxillofac Surg Clin North Am* 1992; **4**: 425–437.
- Robinson PP, Loescher AR, Smith KG. A prospective quantitative study on the clinical outcome of lingual nerve repair. *Br J Oral Maxillofac Surg* 2000; **38**: 255–263.
- LaBlanc JP, Gregg JM. Trigeminal nerve injuries. Basic problems, historical perspectives, early successes and remaining challenges. *Oral Maxillofac Surg Clin North Am* 1992; **4**: 277–283.